

# Indian Journal of Ophthalmology

## HIGHLIGHTS

The sweeter side of retina

Comparing acromegalic patients to healthy controls with respect to intraocular pressure, central corneal thickness, and optic disc topography findings

Morphometric analysis of fovea with spectral-domain optical coherence tomography and visual outcome postsurgery for retinal detachment

Free full text at  
[www.ijo.in](http://www.ijo.in)



Wolters Kluwer  
Health

Medknow



Journal of  
All India Ophthalmological Society

# Morphometric analysis of fovea with spectral-domain optical coherence tomography and visual outcome postsurgery for retinal detachment

Manish Nagpal, Kiran Shakya, Navneet Mehrotra, Kartikey Kothari, Kalyani Bhatt, Rajen Mehta, Chaitanya Shukla

**Purpose:** The purpose of this study was to correlate the postoperative best-corrected visual acuity (BCVA) with spectral-domain optical coherence tomography (SD-OCT) findings in fovea involving rhegmatogenous retinal detachment (RRD) surgery. **Materials and Methods:** Thirty eyes with preoperative fovea-involving RRD, who underwent scleral buckling (SB) (6 eyes) and pars plana vitrectomy (PPV) (19 eyes) and combined SB and PPV (5 eyes) were recruited. Patients underwent clinical examination and SD-OCT scan of fovea preoperatively and at 30 days and 90 days postoperatively. The correlations between SD-OCT findings and BCVA were analyzed. **Results:** Inner segment/outer segment (IS/OS) junction integrity was the indicator of better BCVA at 30 days and 90 days ( $P = 0.0002$  and  $P = 0.0003$ , respectively) whereas outer retinal corrugation (ORC) was related to worse BCVA at 30 days and 90 days ( $P = 0.001$ ). External limiting membrane did not have a co-relation with visual outcome, but cystoid macular edema showed co-relation at 90 days ( $P = 0.047$ ). All eyes of SB and 3 eyes of PPV had a minimal subfoveal fluid at 30 days follow-up that had no effect on visual acuity. All retinas were attached at final follow-up. **Conclusion:** IS/OS junction integrity and ORC may be important predictors of postoperative visual outcome after anatomically successful RRD surgery.

**Key words:** Best-corrected visual acuity, inner segment/outer segment junction, outer retinal corrugation, rhegmatogenous retinal detachment

## Access this article online

### Website:

www.ijo.in

### DOI:

10.4103/0301-4738.141037

## Quick Response Code:



Rhegmatogenous retinal detachment (RRD) causes anatomical distortion which eventually can lead to visual impairment even after successful surgical retinal attachment of fovea. Decreased visual acuity (VA) postoperatively may be due to epiretinal membrane and persistent subretinal fluid.<sup>[1]</sup> Spectral-domain optical coherence tomography (SD-OCT) enables visualization of the foveal images at near-histologic resolution.<sup>[2]</sup> Studies have shown a relation of either the preoperative or postoperative OCT findings with postoperative visual outcome.<sup>[3-8]</sup> This study looked at abnormalities found in SD-OCT preoperatively and postoperatively on day 30 and 90 in patients with fovea involving RRD and correlated these findings with visual outcome.

## Materials and Methods

Thirty eyes of consecutive 30 patients presenting with uncomplicated primary RRD who were to undergo scleral buckling (SB) (6 eyes) and pars plana vitrectomy (PPV) (19 eyes) and combined SB and PPV (5 eyes) surgery were recruited to the study. Patients with preexisting macular pathology (e.g. age-related macular degeneration, macular scars) and history of ocular trauma and those unable to give informed consent were excluded. The fovea was defined as the central retinal depression, approximately 4.0 mm temporal and 0.8 mm inferior to

the center of the optic disc, and was approximately 1.5 mm in diameter. The Institutional Research Board approved the study. Only those patients with preoperative and postoperative SD-OCT (Spectralis HRA + OCT; Heidelberg Engineering, Inc., Heidelberg, Germany) evaluation were included.

All patients were examined preoperatively and at 30 days and 90 days after surgery. They underwent preoperative and postoperative VA testing, slit-lamp biomicroscopy, and dilated fundus examination. Preoperative SD-OCT of all patients was taken on the same day of surgery and post operatively on 30 days and 90 days. Patients with shallow retinal detachments, whose SD-OCT could be recorded, were only included in the study. Other data collected included demographics, duration of symptoms, time to surgery, type of surgical repair, and complications. The OCT characteristics were described and correlated with final visual outcome. Snellen VA was converted to log of the minimum angle of resolution (logMAR) for statistical analysis. The following conversion to logMAR was used for vision worse than 20/400: Counting fingers, 1.6; hand motion, 2.0; light perception, 2.5; and no light perception, 3.0. The statistical  $P$  value was deduced using independent sample  $t$ -test.

## Results

Thirty eyes of patients aged 31-76 years were included (mean age, 53.5 years). 23 patients were male and laterality is equal between right and left eye. Preoperatively, patients had an average symptomatic period of 17.5 days (range, 1-90 days) prior to presentation, which included blurred vision, flashing lights, floaters, or black curtain. The time to surgical

Department of Retina and Vitreous, Retina Foundation, Rajbhavan Road, Ahmedabad, Gujarat, India

**Correspondence to:** Dr. Manish Nagpal, Retina Foundation, Asopalov Eye Hospital, Near Shahibag Underbridge, Shahibag, Ahmedabad, Gujarat, India. E-mail: drmanishnagpal@yahoo.com

Manuscript received: 20.12.13, Revision accepted: 14.07.14

repair from the day of the presentation ranged from 0 to 10 days (mean, 2.2 days). Preoperative VA ranged from 20/30 to hand movement (with accurate recognition of light projection in all quadrants) with mean logMAR of 1.3 [Table 1].

The inner segment/outer segment (IS/OS) junction of the photoreceptors was disrupted in 19 eyes and 23 eyes had outer retinal corrugation (ORC). The external limiting membrane (ELM) was disrupted only in 3 eyes. 20 eyes had cystoid macular edema (CME). The  $P$  value of best-corrected visual acuity (BCVA) between IS/OS junction preserved cases and disrupted cases was 0.36 and between ORC absent cases and ORC present was 0.25 [Table 1].

Inner segment/outer segment junction integrity was the indicator of better BCVA at postoperative 30 days and at 90 days ( $P = 0.0002$  and  $P = 0.0003$ , respectively). The scatter diagram shows there is no significant difference between mean BCVA of IS/OS junction disrupted cases and preserved cases, but it became significant between two groups postoperatively [Fig. 1].

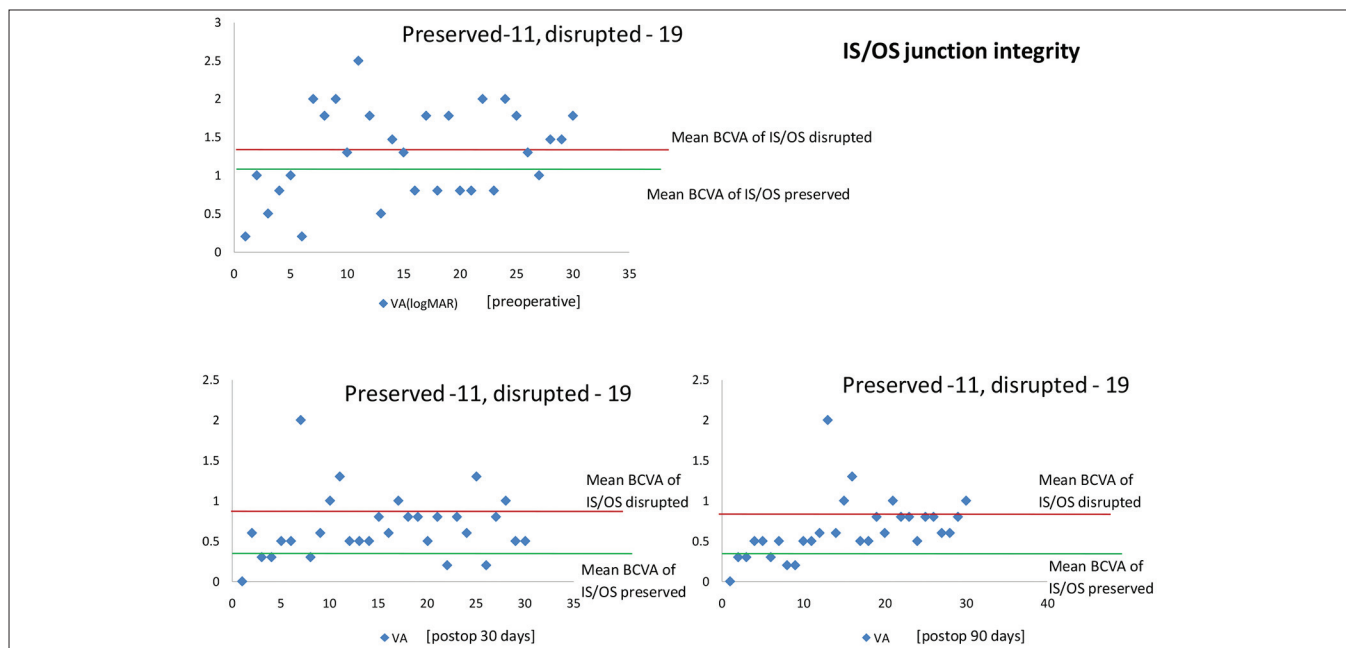
Outer retinal corrugation was related to worse BCVA at postoperative 30 days and at 90 days ( $P = 0.001$ ). The scatter diagram shows ORC was significant for postoperative BCVA [Fig. 2].

External limiting membrane did not show a significant role in visual outcome, but CME showed the role at postoperative 90 days ( $P = 0.047$ ). All eyes of SB and 3 eyes of PPV had a minimal subfoveal fluid at 30 days follow-up that had no effect on VA. All retinas were attached at 90 days postoperatively.

- Spectral-domain optical coherence tomography cases scenario – 1 [Fig. 3]
- Spectral-domain optical coherence tomography cases scenario – 2 [Fig. 4]
- Spectral-domain optical coherence tomography cases scenario – 3 [Fig. 5].

## Discussion

Optical coherence tomography, introduced in the 1990s, is a noninvasive *in vivo* ophthalmic imaging technique.<sup>[9]</sup> SD-OCT



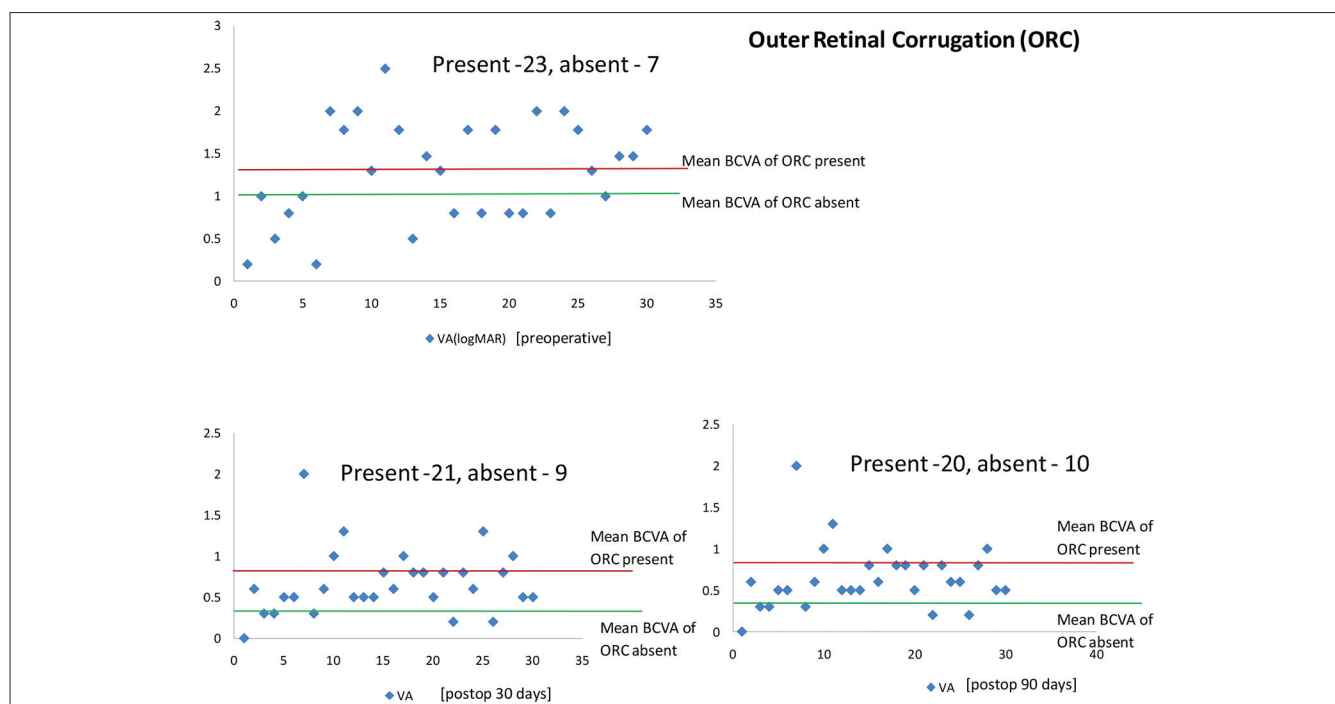
**Figure 1:** Inner segment/outer segment integrity

**Table 1: Preoperative and postoperative results**

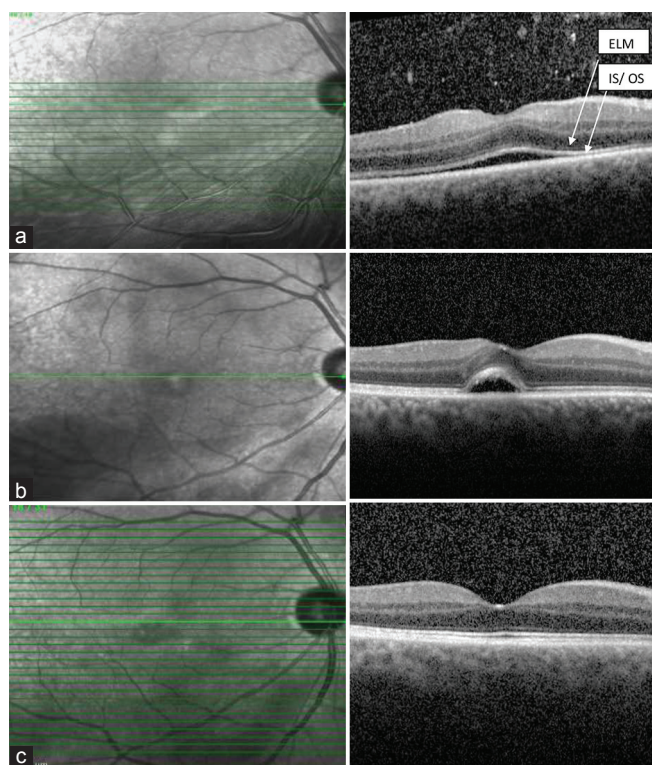
OCT characteristics present	Preoperative		Postoperative 30 days		Postoperative 90 days	
	Number	Mean BCVA	Number	Mean BCVA	Number	Mean BCVA
IS/OS preserved	11	1.14	11	0.37	11	0.36
IS/OS disrupted	19	1.36	19	0.87	19	0.82
ORC absent	7	1.04	9	0.34	10	0.35
ORC present	23	1.35	21	0.82	20	0.8
CME	20	1.23	14	0.8	10	0.84
ELM disrupted	3	1.43	3	1.4	3	1.4

VA measured in logMAR. CME: Cystoid macular edema, IS/OS: Inner segment/outer segment junction, ELM: External limiting membrane, ORC: Outer retinal corrugation, BCVA: Best-corrected visual acuity, SRF: Subretinal fluid, OCT: Optical coherence tomography, VA: Visual acuity, logMAR: Log of the minimum angle of resolution





**Figure 2:** Outer retinal corrugation



**Figure 3:** Preoperative SD-OCT of the right eye of a 51-year-old male with a rhegmatogenous retinal detachment. The fovea is detached. Preoperative BCVA was 20/30. ELM and IS/OS are preserved under the fovea (a). There is no evidence of outer retinal corrugation. There is an absence of cystoid macular edema. The detachment was surgically repaired with a scleral buckling. The BCVA at 30days and 90days postoperatively was 20/20 (b and c) but minimal subretinal fluid is seen on 30 days follow up that has no effect in visual acuity

enables visualization of the foveal images at near-histologic resolution.<sup>[2]</sup>

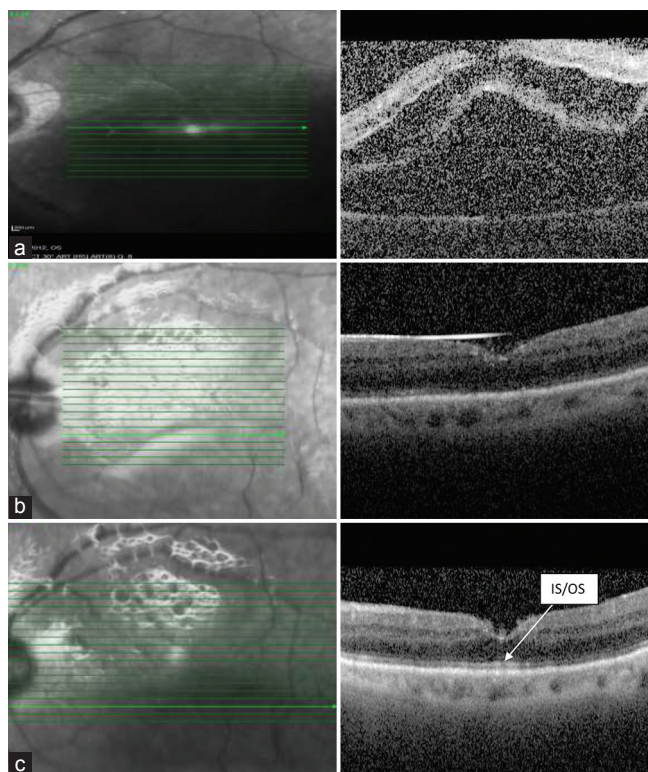
Although there is a successful anatomical attachment in patients with fovea involving RRD, visual outcomes are often less than satisfactory and difficult to predict.<sup>[10-13]</sup> When the fovea becomes detached from the underlying retinal pigment epithelium, its microstructure changes rapidly.

Preoperative predictors are helpful to predict postoperative visual prognosis and aid toward understanding the mechanism of postoperative VA restoration in patients with fovea involving RRD. Different surgical methods may have an impact on the VA and as the sample size of our study was small, we were not able to compare the VA between the groups but it could be done in the future to look at surgical variables.

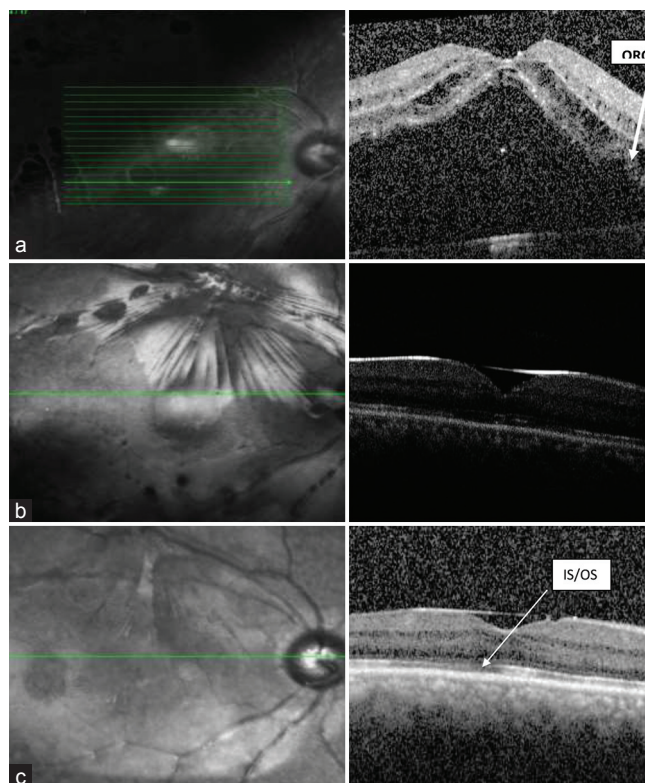
Several reports have analyzed the structural changes found on OCT of the fovea in patients with fovea-involving retinal detachments.<sup>[3,13]</sup> In the present study, IS/OS junction integrity was the indicator of better postoperative VA. Nakanishi *et al.* showed, using their prototype SD-OCT, that a preoperative foveal loss of IS/OS at the detached macula was significantly correlated with postoperative VA.<sup>[6]</sup> A recent study has shown that damage to the IS/OS junction in postoperative SD-OCT image, may explain inadequate postoperative visual recovery.<sup>[1]</sup> The postoperative integrity of the IS/OS junction as a predictor of VA was also subsequently shown in another report.<sup>[5]</sup>

Outer retinal corrugation may indicate more severe photoreceptor damage at the time of detachment. It is also possible that this sign is a manifestation of chronicity for patients with retinal detachment. Postoperatively, the





**Figure 4:** Preoperative optical coherence tomography (OCT) of the left eye of a 60-year-old male with a rhegmatogenous retinal detachment. The macula and the fovea are detached. Preoperative visual acuity (VA) was 20/200. The external limiting membrane (ELM) and the inner segment/outer segment (IS/OS) junction are preserved. There is an absence of outer retinal corrugation and presence of cystoid macular edema (a). The detachment was surgically repaired with a pars plana vitrectomy. The postoperative OCT reveals ELM and IS/OS junction are preserved and ORC is not present (b and c). The BCVA of 30 days and 90 days postoperatively was 20/60 and 20/40 respectively



**Figure 5:** Preoperative SD-OCT of the right eye of a 59-year-old male with a rhegmatogenous retinal detachment. The macula and the fovea are detached. Preoperative visual acuity (VA) was 20/200. The ELM is preserved, but IS/OS junction is disrupted. There is a presence of outer retinal corrugation and presence of cystoid macular edema (a). The detachment was surgically repaired with a pars plana vitrectomy. The postoperative OCT reveals a preserved ELM. IS/OS junction is disrupted and ORC is present (b and c). The BCVA 30 days and 90 days postoperatively remained 20/80

corrugation manifested as ill-defined line instead of clear demarked outer IS/OS junction line. In this study, ORC was related to worse postoperative VA at 30 days and 90 days. Cho *et al.* concluded that ORC was the most predictive of worse preoperative and 1-month postoperative VA.<sup>[14]</sup>

A recent study has shown that damage to the IS/OS junction, with or without disruption of the ELM in postoperative SD-OCT image, may explain inadequate postoperative visual recovery.<sup>[1]</sup>

External limiting membrane did not show any role in visual outcome although the number of cases having ELM disruption case were only 3. Lin *et al.* show low significant difference between ELM preserved group and ELM disrupted group for postoperative visual outcome.<sup>[15]</sup> A limitation of this study is that the number of cases are less and may be larger series would be essential to address these issues.

## Conclusion

Inner segment/outer segment junction integrity and ORC may be important predictors of visual outcome after anatomically successful RRD surgery.

## References

1. Abouzeid H, Wolfensberger TJ. Macular recovery after retinal detachment. *Acta Ophthalmol Scand* 2006;84:597-605.
2. Huang D, Swanson EA, Lin CP, Schuman JS, Stinson WC, Chang W, *et al.* Optical coherence tomography. *Science* 1991;254:1178-81.
3. Lecleire-Collet A, Muraine M, Ménard JF, Brasseur G. Evaluation of macular changes before and after successful retinal detachment surgery using stratus-optical coherence tomography. *Am J Ophthalmol* 2006;142:176-9.
4. Wakabayashi T, Oshima Y, Fujimoto H, Murakami Y, Sakaguchi H, Kusaka S, *et al.* Foveal microstructure and visual acuity after retinal detachment repair: Imaging analysis by Fourier-domain optical coherence tomography. *Ophthalmology* 2009;116:519-28.
5. Lai WW, Leung GY, Chan CW, Yeung IY, Wong D. Simultaneous spectral domain OCT and fundus autofluorescence imaging of the macula and microperimetric correspondence after successful repair of rhegmatogenous retinal detachment. *Br J Ophthalmol* 2010;94:311-8.
6. Nakanishi H, Hangai M, Unoki N, Sakamoto A, Tsujikawa A, Kita M, *et al.* Spectral-domain optical coherence tomography imaging of the detached macula in rhegmatogenous retinal detachment. *Retina* 2009;29:232-42.
7. Hagimura N, Suto K, Iida T, Kishi S. Optical coherence tomography of the neurosensory retina in rhegmatogenous retinal detachment. *Am J Ophthalmol* 2000;129:186-90.

8. Wolfensberger TJ. Foveal reattachment after macula-off retinal detachment occurs faster after vitrectomy than after buckle surgery. *Ophthalmology* 2004;111:1340-3.
9. Puliafito CA, Hee MR, Lin CP, Reichel E, Schuman JS, Duker JS, *et al.* Imaging of macular diseases with optical coherence tomography. *Ophthalmology* 1995;102:217-29.
10. Lecleire-Collet A, Muraine M, Menard JF, Brasseur G. Predictive visual outcome after macula-off retinal detachment surgery using optical coherence tomography. *Retina* 2005;25:44-53.
11. McPherson AR, O'Malley RE, Butner RW, Beltangady SS. Visual acuity after surgery for retinal detachment with macular involvement. *Ann Ophthalmol* 1982;14:639-45.
12. Yazici B, Gelisken O, Avci R, Yücel A. Prediction of visual outcome after retinal detachment surgery using the Lotmar visometer. *Br J Ophthalmol* 2002;86:278-81.
13. Friberg TR, Eller AW. Prediction of visual recovery after scleral buckling of macula-off retinal detachments. *Am J Ophthalmol* 1992;114:715-22.
14. Cho M, Witmer MT, Favarone G, Chan RP, D'Amico DJ, Kiss S. Optical coherence tomography predicts visual outcome in macula-involving rhegmatogenous retinal detachment. *Clin Ophthalmol* 2012;6:91-6.
15. Lin HC, Yeh PT, Huang JS. Optical coherence tomography study of foveal microstructure after successful retinal detachment surgery.

**Cite this article as:** Nagpal M, Shakya K, Mehrotra N, Kothari K, Bhatt K, Mehta R, *et al.* Morphometric analysis of fovea with spectral-domain optical coherence tomography and visual outcome postsurgery for retinal detachment. *Indian J Ophthalmol* 2014;62:846-50.

**Source of Support:** Nil. **Conflict of Interest:** None declared.