

Case Report

Posterior Vitreous Detachment (PVD) Creation Leading to Intraoperative Retinal Detachment during Surgery for Idiopathic Macular Hole

Manish Nagpal*, Rakesh Juneja, and Pranita Chaudhary

Eye Research Centre and Retina Foundation, India

*Corresponding author

Manish Nagpal, Eye Research Centre and Retina Foundation, near underbridge, Rajbhavan road, Shahibag, Ahmedabad-4, Gujarat, India, Tel: 91-079-22865537; Fax: 91-079-22866381; Email: drmanishnagpal@yahoo.com

Submitted: 11 April 2017

Accepted: 25 April 2017

Published: 27 April 2017

ISSN: 2333-6447

Copyright

© 2017 Nagpal et al.

OPEN ACCESS

Keywords

- Macular hole
- Posterior vitreous detachment
- Endolaser barrage

Abstract

Purpose: To report case of a patient who developed intraoperative supero-nasal retinal detachment during surgery for idiopathic macular hole.

Methods: Interventional Case report of a 62-year-old male who presented with macular hole in both eyes and underwent surgery for macular hole closure in RE.

Results: On presentation, visual acuity was 20/60 in RE and 20/200 in LE. Optical coherence tomography (OCT) examination revealed an old long standing stage IV macular hole in LE & a recent onset stage III macular hole in RE. In RE, pars planavitreotomy was undertaken. During the process of posterior vitreous detachment (PVD) creation, a localized area of retina appeared white and oedematous supero-nasally, at 3 o'clock. When hyaloid was pulled in this region, it led to the creation of intraoperative retinal detachment. Brilliant blue green dye was then injected to stain and peel the internal limiting membrane (ILM) followed by fluid-air exchange and drainage of sub-retinal fluid from the break. Endolaser barrage was done around the break in 3-4 circular rows to oppose the retina with underlying choroid and to barrage the area of oedematous retina with detachment. C3F8: air (0.3:0.7) mixture was injected to provide internal tamponade followed by prone positioning post-operatively for ten days. 4 weeks post-operatively, his visual acuity improved to 20/40 with complete reattachment of the retina and closure of macular hole.

Conclusion: While surgery for macular hole is both, safe and effective, iatrogenic retinal breaks will always be a part of vitrectomy, despite progress in instrumentation and techniques.

ABBREVIATIONS

OCT: Optical Coherence Tomography; PPV: Pars Plana Vitrectomy; RD: Retinal Detachment; RE: Right Eye; LE: Left Eye; IVTA: Intravitreal Triamcinolone Acetonide; ILM: Internal Limiting Membrane

INTRODUCTION

Idiopathic macular holes result in significant deterioration of central visual acuity. Its prevalence is 0.05% in general population [1,2]. Kelly & Wendel in 1991 proposed pars plana vitrectomy (PPV) for closure of full thickness macular hole which resulted in significant improvement of anatomical and functional outcome [3,4]. However, this procedure carries certain risks and may result in various complications like cataract, high intraocular pressure, retinal vascular occlusion, intraocular inflammation, endophthalmitis, cystoid macular oedema, phototoxicity, retinal breaks, retinal detachment (RD) and surgery failures [4,5].

One of the major and well-known complications of PPV is the formation of iatrogenic retinal break. Its incidence ranges

from 2-25% [2,6]. Instrumentation can cause retinal tear which occurs along the vitreous base due to traction and incarceration of vitreous in the sclerotomy site [6]. Despite the advancements in wide angle viewing systems and PPV surgery, post PPV-RDs secondary to iatrogenic retinal break is a major sight-threatening condition which is known to occur in a range from 0-15.8% [7].

Herein, we describe case of a 62 year-old male who developed a supero-nasal retinal detachment during surgery for macular hole.

CASE PRESENTATION

A healthy 62-year-old male patient presented with best-corrected visual acuity of 20/60 in right eye (RE) and 20/200 in left eye (LE). Optical coherence tomography (OCT) examination revealed a recent onset stage III macular hole in RE and an old long standing stage IV macular hole in LE (Figure 1 & 2). In RE, PPV was undertaken and core vitrectomy was carried out. After that, intravitreal triamcinolone acetonide (IVTA) was injected to stain the hyaloid. High vacuum was used to gradually pull the hyaloid away from the posterior pole. The hyaloid detached from

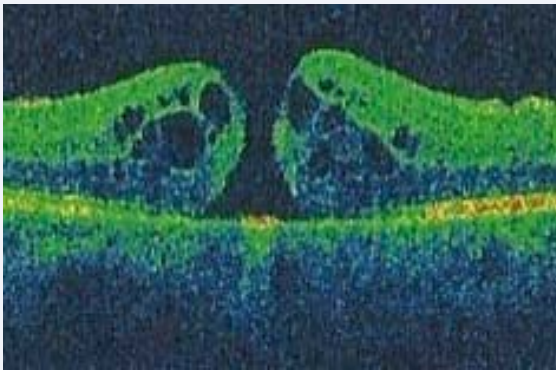


Figure 1 Pre-operative OCT examination RE showing recent onset stage III full thickness macular hole.

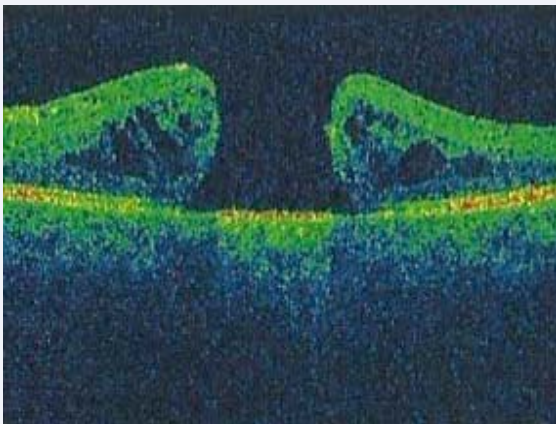


Figure 2 Pre-operative OCT examination LE showing old long standing stage IV full thickness macular hole.

the disc and gradually the macular area. After this the hyaloid detachment was extended to the periphery. In the supero-nasal area, suddenly there was a lot of resistance and a localized area of retina appeared oedematous. As we pulled the hyaloid in this area, we noted a RD coming up (Figure 3). Without using further vacuum, the adherent vitreous in that region was trimmed with the cutter.

At this stage, peeling of the internal limiting membrane (ILM) was done after staining with brilliant blue green dye (Figure 4). Post ILM removal, fluid-air exchange was carried out followed by drainage of sub-retinal fluid from the break (Figure 5). Endolaser barrage was done around the break in 3-4 circular rows to oppose the retina with underlying choroid and to barrage the area of oedematous retina with detachment (Figure 6). C_3F_8 : air (0.3:0.7) mixture was injected to provide internal tamponade. Patient was advised prone positioning for the next ten days.

4 weeks post-operatively, his visual acuity improved to 20/40 with complete reattachment of the retina and closure of macular hole evident on fundus and OCT examination (Figure 7a, 7b & 8).

DISCUSSION

PPV with ILM peeling and gas tamponade is the treatment modality for full thickness macular hole. As more of these surgeries

are performed, various complications have been reported. Intraoperative iatrogenic retinal breaks and intraoperative/post-operative RD are amongst the most common serious complications of macular hole surgery. Sjaarda et al., reported 10 (5.5%) iatrogenic retinal breaks and 2 (1.1%) postoperative RDs in 181 eyes with macular holes [6]. The incidence of retinal break varies considerably from 3 to 14% and of RD from 2 to 14% across the published reports [5,8,9]. With the advent of MIVS, the incidence is now probably at the lower end of this range. In 25-gauge vitrectomy, incidence of retinal breaks was reported to be 0% to 3.1% [10,11].

Retinal breaks occurring during macular hole surgery and resulting in RD are postulated to occur due to perpendicular tractional forces occurring on the vitreous base during

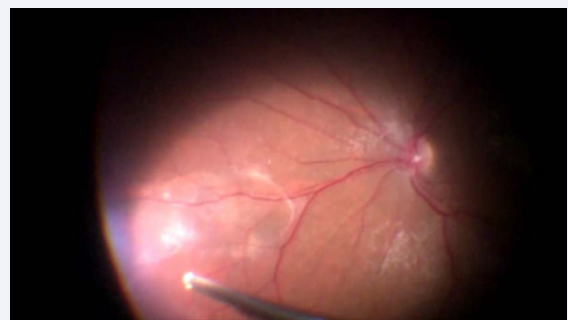


Figure 3 RE showing oedematous & white area of retina supero-nasally at 3 o'clock position with formation of retinal detachment during removal of hyaloid after staining with IVTA.

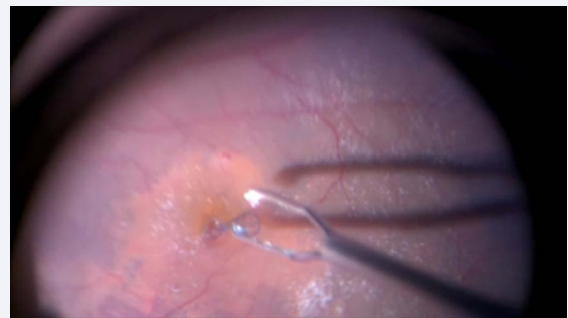

Figure 4 Peeling of the internal limiting membrane (ILM) after staining with brilliant blue green dye.

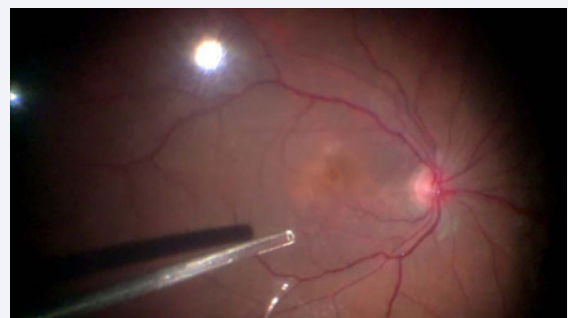

Figure 5 Fluid-air exchange done post ILM removal.

intraoperative creation and extension of a PVD. In a study comparing the incidence of iatrogenic retinal breaks with or without preoperative PVD in patients with macular hole, retinal breaks were detected in 12.7% with induction of PVD and in 3.1% without induction of PVD [8]. Further, the difference in the incidence of retinal break in various studies may be attributable to the surgical techniques used to initiate and advance PVD.

Previous series have suggested that the majority of retinal breaks associated with macular hole surgery were located

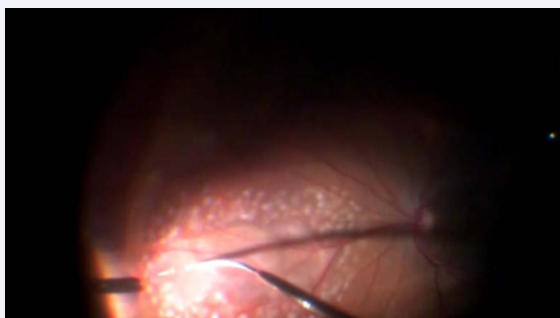


Figure 6 Endolaser barrage around the break in 3-4 circular rows.

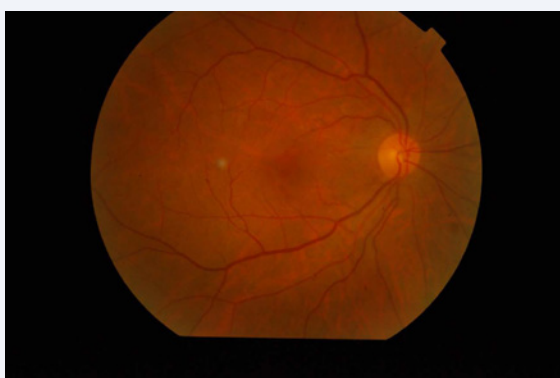

Figure 7a 4 weeks post-operative color fundus photograph RE showing complete closure of macular hole.

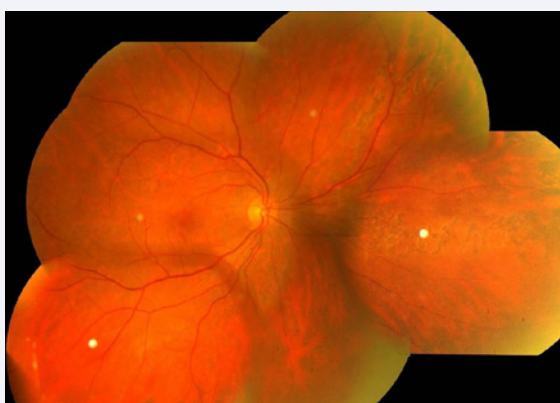

Figure 7b 4 weeks post-operative montage color fundus photograph RE showing complete closure of macular hole and retinal break with complete reattachment of retina at the site of retinal break.

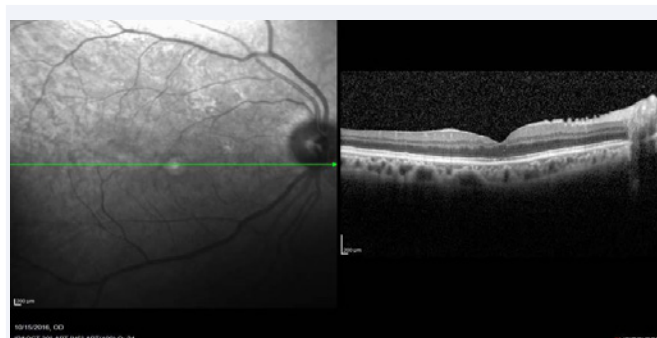


Figure 8 4 weeks post-operatively OCT examination RE showing complete closure of macular hole with normal foveal contour.

inferiorly [4,6,12]. A possible explanation may be that natural PVD usually starts superiorly and that inferior PVD is often incomplete. Also, the entry of cutter and light pipe may induce an a traumatic separation of the vitreous superiorly. This explains the predilection for inferior tears, as during surgery, PVD needs to be induced more often in the inferior region. A similar distribution of retinal break associated with macular hole surgery was found by Sjaarda et al [6].

However, some RDs do occur secondary to superior retinal breaks. A previous study noted that in 57 eyes with stage 4 macular hole, where intraoperative PVD induction was not required, superior tears were noted in 2, whereas none had inferior tears [6]. Hence, it has been postulated that, superior breaks, especially in the retinal quadrant near the sclerotomy of the surgeon's dominant hand, are caused by traction at the sclerotomy site during the manipulation of instruments or due to vitreous incarceration [4].

In our case, after staining the posterior vitreous cortex with IVTA, the attached cortical vitreous was engaged with active suction by a cutter and PVD was extended to the peripheral retina. While separating the posterior vitreous cortex in the supero-nasal quadrant, a strong vitreo-retinal adherence was noted. Hyaloid in that region was extremely adherent and with every attempt to peel the hyaloid the retina seemed to get oedematous and white in colour and also started to lift up causing a localized retinal detachment. This is an unusual case of persistent vitreo-retinal adherence in the superior region with formation of a superior break and RD during PVD induction.

The break and the adjacent retina were cordoned off with endolaser photocoagulation. Long acting gas provided effective tamponade against the superior break as well as provided a surface for effectively bridging the full thickness macular hole.

While surgery for macular hole is both, safe and effective, iatrogenic retinal breaks will always be a part of vitrectomy, despite progress in instrumentation and technique. Hence, surgeons must be cautious, especially during PVD induction as retinal breaks may accompany. A careful intraoperative examination and recognizing the characteristics of breaks remains the mainstay to limit the risk of potentially serious complications.

REFERENCES

1. Lewis ML, Cohen SM, Smiddy WE, Gass JD. Bilaterality of idiopathic macular holes. *Graefes Arch Clin Exp Ophthalmol*. 1996; 234: 241-245.
2. Tabandeh H, Chaudhry NA, Smiddy WE. Retinal detachment associated with macular hole surgery: characteristics, mechanism, and outcomes. *Retina*. 1999; 19: 281-286.
3. Kelly NE, Wendel RT. Vitreous surgery for idiopathic macular holes. Results of a pilot study. *Arch Ophthalmol*. 1991; 109: 654-659.
4. Heier JS, Topping TM, Frederick AR Jr, Morley MG, Millay R, Pesavento RD. Visual and surgical outcomes of retinal detachment following macular hole repair. *Retina*. 1999; 19: 110-115.
5. Guillaubey A, Malvitte L, Lafontaine PO, Hubert I, Bron A, Berrod JP, et al. Incidence of retinal detachment after macular surgery: a retrospective study of 634 cases. *Br J Ophthalmol*. 2007; 91: 1327-1330.
6. Sjaarda RN, Glaser BM, Thompson JT, Murphy RP, Hanham A. Distribution of iatrogenic retinal breaks in macular hole surgery. *Ophthalmology*. 1995; 102: 1387-1392.
7. Dogramaci M, Lee EJ, Williamson TH. The incidence and the risk factors for iatrogenic retinal breaks during pars plana vitrectomy. *Eye (Lond)*. 2012; 26: 718-722.
8. Chung SE, Kim KH, Kang SW. Retinal breaks associated with the induction of posterior vitreous detachment. *Am J Ophthalmol*. 2009; 147: 1012-1016.
9. Park SS, Marcus DM, Duker JS, Pesavento RD, Topping TM, Frederick AR Jr, et al. Posterior segment complications after vitrectomy for macular hole. *Ophthalmology*. 1995; 102: 775-778.
10. Patelli F, Radice P, Zumbo G, Frisone G, Fasolino G. 25-gauge macular surgery: results and complications. *Retina*. 2007; 27: 750-754.
11. Faia LJ, McCannel CA, Pulido JS, Hatfield RM, Hatfield ME, McNulty VEW. Outcomes following 25-gauge vitrectomies. *Eye*. 2008; 22: 1024-1028.
12. Tan HS, Mura M, de Smet MD. Iatrogenic retinal breaks in 25-gauge macular surgery. *Am J Ophthalmol*. 2009; 148: 427-430.

Cite this article

Nagpa M, Juneja R, Chaudhary P (2017) Posterior Vitreous Detachment (PVD) Creation Leading to Intraoperative Retinal Detachment during Surgery for Idiopathic Macular Hole. *JSM Ophthalmol* 5(1): 1051.