

Indian Journal of Ophthalmology

Please follow the instructions in this letter carefully.

Attached is a page proof of your article, which is scheduled for publication in a forthcoming issue of IJO which is being sent to you for proof check.

Its purpose is for the essential correction of errors only, to check the accuracy and positioning of tables and figures and/or approval that no further corrections are required.

Proof corrections

- Please add corrections or answers to any queries by typing or writing them clearly on page proof or mention the corrections separately with details [Page number, paragraph number, right/left column, line number, corrections (Replace “.....” with “.....”)]
- Please check the accuracy of items such as author details
- Please check the accuracy and positioning of tables and figures
- Please check for the corruption of special characters such as symbols and Greek letters
- **No free reprints are provided. Contact us if you wish to purchase reprints.**

Return your corrections to:

E-mail: proofs@medknow.com **OR by courier/speed post to:**

MEDKNOW PUBLICATIONS, 12, Manisha Plaza, MN Road, Kurla (W), Mumbai – 400 070, INDIA

Last Date to Return the Proofs

10/06/2005

Role of early radial optic neurotomy in Central Retinal Vein Occlusion

Manish Nagpal, MS, DO, FRCS (UK); Kamal Nagpal, MS, DO; Chirag Bhatt, MS; Pran N Nagpal, MS, FACS

Purpose: To determine safety, clinical and visual results, and potential complications of early radial optic neurotomy (RON) surgery in eyes with central retinal vein occlusion (CRVO), with relative afferent pupillary defect and visual acuity < 6/60.

Materials and Methods: This prospective, interventional case-series included 24 patients of CRVO who underwent RON within 2 months of disease onset.

The preoperative examination included slitlamp biomicroscopy, fundus photography and fluorescein angiography. Foveal thickness was measured using optical coherence tomography (OCT) in the last 6 eyes only. In each case, RON was performed after informed consent. Two radial incisions were placed in the nasal quadrant of the optic disc, using a micro-vitreoretinal blade. The postoperative change in vision, clinical picture, fundus photographs, angiograms and foveal thickness by OCT were the main outcome variables studied. The Wilcoxon signed test was used to assess the results.

Results: Average symptom duration was 37.8 ± 15.2 days (range 15-60 days, median: 34.5 days) and follow-up 7.7 ± 2.1 months (range 1-12 months, median: 8 months). Visual outcome: 2 (8.33%) eyes each had fall and preservation of pre-RON visual acuity respectively. Twenty eyes (83.33%) showed increase in vision (of average 3 lines). Pre and postoperative vision ranged from 0.017-0.1 (average:0.061) and 0.017-0.667 (average: 0.17) respectively ($P < 0.05$). Clinical and angiographic outcome: Decline in macular oedema, decreased or resolved intraretinal haemorrhages, resolution of venous dilatation and disc oedema could be appreciated in all cases. Foveal thickness: Average pre and postoperative foveal thickness was $834.17 \mu\text{m}$ and $556.17 \mu\text{m}$ respectively ($P < 0.05$) in the 6 eyes where it was measured before and after RON. One eye developed retinal-detachment.

Conclusion: Radial optic neurotomy is better than the natural course in eyes with CRVO, with vision <6/60.

Key Words: Central retinal vein occlusion, Radial optic neurotomy, Relative afferent pupillary defect, Optical coherence tomography, Optic disc

Indian J Ophthalmol 2005;53:85-??

Retinal vein occlusions are complex, multi-factorial disease phenomena. Amalgamation of predisposing and precipitating risk factors, both systemic (i.e. arterial hypertension) and local (i.e. increased arterial diameter, connective tissue and collagen changes in the scleral ring, presence of anatomical anomalies, increased turbulence, endothelial damage, etc) in critical numbers and/or intensity may lead to the final catastrophic event of central retinal vein occlusion (CRVO).¹ Nonischaemic CRVO may be due to obstruction of the central retinal vein (CRV) and ischaemic CRVO, due to obstruction of both the central retinal artery (CRA) and the central retinal vein.²

Local factors present in the eye or the vein itself are currently being looked at carefully so as to design a possible surgical care. Histologic studies have localised lamina cribrosa as the site for thrombus formation (as a primary or secondary event) in most or all cases.^{3,4} Opremcak *et al*⁵ hypothesised that the aetio-pathogenesis of CRVO is similar to "compartment syndromes" elsewhere in the body, where pressure within a confined space results in tissue ischaemia. The internal diameter of the optic disk and scleral outlet is 1.5 mm. The optic nerve comprises myelinated optic nerve, CRA and CRV, and as it enters the eye has a diameter of 3 mm. The myelinated nerve fibres lose their myelin sheaths as they pass through the lamina cribrosa. This results in an anatomic "bottleneck" where within a 1.5-mm-diameter area, lie the CRA, CRV and optic nerve. The dense connective tissue of the lamina cribrosa encircling these structures restricts the central retinal vein luminal diameter.⁶ Thus, the importance of this site (lamina cribrosa) in pathogenesis and possible surgical treatment for CRVO, has been emphasised.^{5,6} Opremcak *et al*⁵ and

Retina Foundation, Ahmedabad, India

Proprietary Interest: None

Correspondence to Dr. Kamal Nagpal, Retina Foundation, Near Shahibag Underbridge, Rajbhavan Road, Ahmedabad - 380 004, India. E-mail: <manishad1@sancharnet.in>

Manuscript received: 24.4.04; Revision accepted: 31.1.05

Garcia-Arumi *et al*⁷ performed surgical decompression of CRVO by radial optic neurotomy (RON) (in 11 and 14 cases respectively) with resultant reperfusion of retina and a promised stabilisation to improvement in the course of severe CRVO. Lit, *et al*⁸ coined the term *lamina puncture* for a similar procedure and suggested that it should be recommended in select patients.

The natural history of eyes with CRVO is largely dependent upon the state of ischaemia and visual acuity at initial presentation. The Central Vein Occlusion Study^{8,9} reported that in 6.5% instances with presenting vision better than 20/40, the vision stabilizes. Patients with poor visual acuity at presentation (< 20/200) had an 80% chance of having a visual acuity less than 20/200 at the final visit. In the first 4 months of follow-up, 15% of eyes with perfusion converted to ischaemia. During the next 32 months of follow-up, an additional 19% eyes converted to ischaemia and thus it was 34% after 3 years. The development of nonperfusion or ischaemia was most rapid in the first 4 months and progressed continuously throughout the duration of follow-up. In patients with intermediate vision (20/50 to 20/200), 44% of eyes remained stable while 37% worsened. Moreover, 30% of eyes converted from non-ischaemic to ischaemic CRVO.

In view of the grim natural history of eyes with CRVO with initial vision less than 6/60 and earlier reports of benefits following RON we designed a prospective interventional trial of RON on eyes with CRVO. Our objective was to determine the safety, clinical and visual improvement, and potential complications of this procedure.

Materials and Methods

Enrolment and preoperative evaluation

This prospective, uncontrolled, interventional case series included 24 patients with CRVO (within two months from onset), who underwent RON. Inclusion criteria were the presence of relative afferent pupillary defect (RAPD) of 0.9 log units of neutral density filters and visual acuity of 6/60 or worse (caused by macular oedema and haemorrhages secondary to CRVO). Patients with CRVO and vision of 6/36 or greater were excluded from the study. We excluded eyes with retinal neovascularisation, neovascular glaucoma, areas of capillary non-perfusion on angiography and history of previous laser photocoagulation and vitreous haemorrhage.

Complete medical and ophthalmic history, including age, gender, laterality, duration of symptoms, and risk factors such as hypertension, diabetes, open-angle glaucoma, hyperlipidemia, was recorded. All patients underwent retinoscopy. Best corrected Snellen visual acuity was recorded by the smallest line managed by the patient (one error was allowed). Intraocular pressure (IOP) measurement and slitlamp examination of the anterior segment were done. Swinging flashlight test was performed in each case to detect the presence of RAPD, which was then quantified by using neutral density filters. Increasing density of filter was placed before the healthy eye, in conjunction with the swinging flashlight until af-

ferent pupillary defect disappeared or reversed. Fundus examination included indirect ophthalmoscopy and slitlamp biomicroscopy of vitreous and retina. Fundus photography and fluorescein angiography were performed in each case. While the study was continuing, we acquired the optical coherence tomography (OCT) (model 3000; Humphrey Instruments, San Leandro, Calif). Foveal thickness was measured using the OCT in all (six) patients enrolled after this period.

Operative procedure

After detailed counselling regarding the natural history of the disease and pros and cons of the surgery, informed consent was obtained and patients posted for surgery. All procedures were performed by the same surgeon (MN). Following standard 3-port pars plana vitrectomy, a posterior hyaloid detachment was created using a vitreous cutter in the aspiration mode. A standard microvitreoretinal (MVR) blade was used to perform RON. The nasal quadrant of the optic disc was chosen in order to avoid the maculopapillary nerve fibres. The incision was fashioned parallel to the nerve fibres - radial to the optic disc - in order to split apart the nerve fibres, rather than transect them. The tip of the MVR blade was placed at the edge of the optic disk, taking care to avoid all major branches and tributaries of central retinal vessels. The blade was then gently pushed posteriorly into the optic nerve up to the widest diameter of the tip; the depth of penetration was 2.5 mm. The purpose of such a stab was to make a relaxing incision at the level of the cribriform plate and adjacent scleral ring. We placed two such separate stab incisions (the second incision at 90 degrees to the first) in each case. If there was a trickle of blood from the incision, the intraocular pressure was raised to 60 mmHg for a minute to minimise the bleed. The residual blood was aspirated from the vitreous cavity with a flute needle. A soft tipped cannula attached to a flute handle was gently brushed over the retinal surface, overlying the superficial retinal haemorrhages. This resulted in passive aspiration and clearing of blood to some extent. After this, we injected 3-4cc liquid perfluorocarbon (PFCL) over the posterior pole. This was done with the aim of mechanically squeezing oedematous fluid away from the macular area. It was left inside for a period of five minutes and in the meantime we assessed the periphery of the retina and treated any breaks or iatrogenic lesions which were detected. Finally, air-fluid exchange was carried out and the PFCL removed.

Postoperative evaluation

Patients were discharged from the hospital after examination the day after the surgery. They were scheduled for postoperative follow-up after a week, a month, three months and six months. At each visit, changes in best-corrected Snellen visual acuity, clinical improvement in terms of decline in macular oedema, decreased or resolved intraretinal haemorrhages, appearance of the disc, its margins, and the veins were studied clinically. Postoperative fundus photographs were obtained and compared with preoperative photographs. Fluorescein

angiograms were obtained (at 1 month following surgery). Foveal thickness was measured by OCT (in the last six cases).

Statistical analysis

Snellen visual acuity was converted into corresponding decimal values, as described elsewhere.¹⁰ Nonparametric statistical methods were used to assess results. The relationship between preoperative and postoperative visual acuity and foveal thickness (measured by OCT in 6 eyes) was calculated using the Wilcoxon signed test for paired samples. $P < .05$ was considered statistically significant.

Results

The clinical details of 24 consecutive patients (16 males, 8 females) are shown in Table 1. The patient age was 54.1 ± 12.04 years (range: 30-80 years, median: 53). Twelve patients were hypertensive and 5 diabetic. Four (16.67%) patients had both hypertension and diabetes. The average duration of symptoms at the time of surgery was 37.8 ± 15.2 days (range 15-60 days, median: 34.5). The average follow-up was 7.7 ± 2.1 months (range 1-12 months, median: 8). Patient # 6 was lost to follow-up after one month.

Visual outcome [Figure 1]

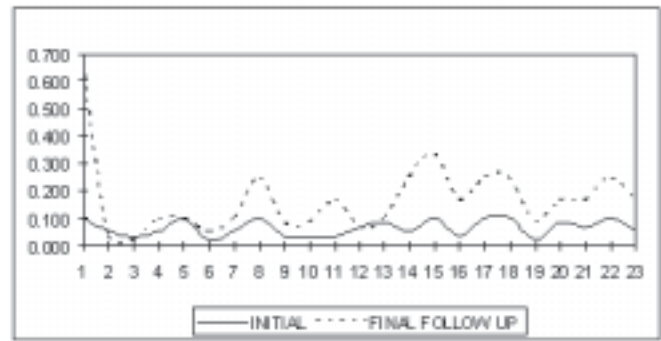


Figure 1: Pre and post-RON visual curves

Two (8.33%) patients (#2,3) had a reduction in vision by one line each. Patient #3 developed retinal-detachment and despite successful re-attachment, did not regain the pre-RON visual acuity. Two (8.33%) patients (#5,13) maintained the pre-RON visual acuity. Twenty eyes (83.33%) showed an increase in visual acuity by one or more lines. An average improvement of 3 lines was observed in these patients, with a maximum improvement of 5 lines in 4 eyes.

Preoperative visual acuity ranged from 0.017-0.1 (average: 0.061 ± 0.031 , median:0.05). Postoperative vision at final follow-up ranged from 0.017-0.667 (average: 0.17 ± 0.14 , median:0.17). The difference between the preoperative and postoperative visual acuity levels was

Table 1: Visual outcome of RON

Patient No.	Age (years)	Duration (days)	Pre-RON VA	1 st month VA	Final VA	Total follow-up (months)
1	35	25	0.100	0.250	0.667	6
2	42	60	0.050	0.033	0.033	6
3	56	30	0.033	0.100	0.017	12
4	48	60	0.050	0.050	0.100	8
5	64	48	0.100	0.100	0.100	8
6	65	60	0.017	0.033	Lost to follow-up	1
7	60	30	0.017	0.033	0.050	8
8	80	60	0.050	0.050	0.100	8
9	48	60	0.100	0.167	0.250	10
10	57	60	0.033	0.050	0.083	8
11	30	26	0.033	0.050	0.083	9
12	42	15	0.033	0.167	0.167	6
13	48	45	0.067	0.050	0.067	8
14	54	30	0.083	0.167	0.100	6
15	60	28	0.050	0.167	0.250	8
16	58	25	0.100	0.250	0.333	6
17	46	37	0.033	0.100	0.167	10
18	71	20	0.100	0.250	0.250	8
19	52	36	0.100	0.167	0.250	10
20	50	34	0.017	0.067	0.083	8
21	56	15	0.083	0.100	0.167	8
22	78	40	0.067	0.167	0.167	7
23	48	35	0.100	0.167	0.250	10
24	50	30	0.050	0.100	0.167	6.5

RON – Radial optic neurotomy; VA – Visual acuity

statistically significant ($P < 0.05$).

Clinical outcome

Clinical improvement, ranging from subtle to striking could be seen in all the cases. Important features included a decline in macular oedema, decreased or resolved intraretinal haemorrhages, resolution of the venous dilatation, resolution of disc oedema and clearing up of its margins. Linear scar could be appreciated at the site of neurotomy. No eye developed retinal neovascularisation, iris neovascularisation, or neovascular glaucoma postoperatively [Figures 2a and b].

Fluorescein angiographic (FA) evidence of venous reperfusion

In FA, resolution of macular oedema, disc oedema, venous tortuosity and dilatation and reduction of areas of blocked fluorescence due to haemorrhages could be appreciated. No eye developed areas of capillary non-perfusion or retinal neovascularisation postoperatively [Figures 2c and d].

Foveal thickness [Table 2]

Foveal thickness was measured on OCT in the last 6 cases (#19-24). The preoperative foveal thickness ranged from 593 to 1197 μm (average: $834.2 \pm 213.65 \mu\text{m}$, median: 801 μm), the postoperative thickness ranged from 355 to 641 μm (average: $556.2 \pm 107.2 \mu\text{m}$, median: 597 μm). This change in foveal thickness following the surgery was statistically significant ($P < 0.05$) [Figures 2e and f].

Complications

Four eyes were detected during surgery to have suspicious peripheral lesions, and were treated with cryopexy. Intra-operative ooze of blood at the site of neurotomy occurred in 5 eyes, and was controlled easily by raising the intraocular pressure. One case (patient #3) developed total rhegmatogenous retinal-detachment from 9-1 o'clock, with a horseshoe tear at 11 o'clock in the postoperative period. This patient had a 4-line improvement in visual acuity at first month following the procedure. He developed retinal detachment 2 months following the surgery. The patient received vitrectomy with C_3F_8 gas injection, followed by repeat vitrectomy with silicon oil injection for retinal re-attachment. At final follow-up, one year after RON, he had a vision of 1/60, one line worse than his initial vision. Other than this case, we did not

see any other major complications.

Discussion

The natural course of CRVO, in eyes presenting with vision less than 6/60, is frustrating - both for the patient and the surgeon. Laser treatment is often inadequate. Pan-retinal laser photocoagulation appears effective only in managing neovascular complications, while grid macular laser decreases macular oedema without changing the final vision.¹¹ Chorio-retinal anastomosis using high intensity laser photocoagulation¹²⁻¹⁵ has been found useful in 30% cases, but with a high rate of complication such as haemorrhages, branch retinal vein occlusion (BRVO), fibrosis, traction and retinal detachment.

The need for effectual remedial options for CRVO has been driving the development of novel surgical methods. Fekrat and de Juan¹⁶ describe an eye with CRVO that developed chorioretinal anastomoses following transvitreal venipuncture at the larger second and third order retinal vessels in eyes with ischaemic CRVO. Thrombolytic agents have been used for pharmacological dissolution of thrombus at the level of the lamina cribrosa. Recombinant tissue plasminogen activator was either injected into the vitreous cavity^{17,18} or cannulated into a retinal vein.^{19,20} Moderate improvement without significant adverse effects was reported.¹⁸ Although capable of restoring blood flow, such treatment does not relieve the constriction of CRV at lamina cribrosa. On the contrary, endothelial cell proliferation due to venipuncture may further limit lumen size. However, it may be of interest to explore the combination of local delivery of a thrombolytic agent along with lamina puncture, as both are different approaches to the same pathophysiologic dysfunction.⁶

In order to relieve the constriction, the sclera surrounding the optic nerve was initially incised externally.²¹⁻²³ However, lamina cribrosa, the most common site for thrombus formation^{3,4} is most easily and directly approached through the internal route.⁵⁻⁷

Our operative procedure is similar to that described by Opremcak *et al*.⁵ However, since the procedure is essentially blind, with no visible end point, we elected to put two incisions in order to increase the chances of success. A soft-tipped cannula attached to a flute handle was then gently brushed over the retinal surface, overlying the superficial retinal haemorrhages. This resulted in passive aspiration and clearing of blood to some extent. Furthermore, we used PFCL injection over the posterior pole for a period of five minutes at the completion of the surgery to mechanically squeeze out oedematous fluid from the macula.

In our series, 2 (8.33%) patients maintained the pre-RON visual acuity, while 20 eyes (83.33%) showed an increase in visual acuity by one or more lines. These results are slightly better than those of Opremcak *et al*,⁵ who have reported equal or better postoperative visual acuity in 82% patients and improvement in 73%. This difference could be due to our strict inclusion criteria of

Table 2: Foveal thickness on optical coherence tomography

Patient No.	Pre-RON	Post-RON
19	934	641
20	768	584
21	1197	626
22	834	610
23	679	521
24	593	355




Figure 2a: CRVO with macular oedema, extensive haemorrhages, venous dilatation, and disc oedema are seen in right eye

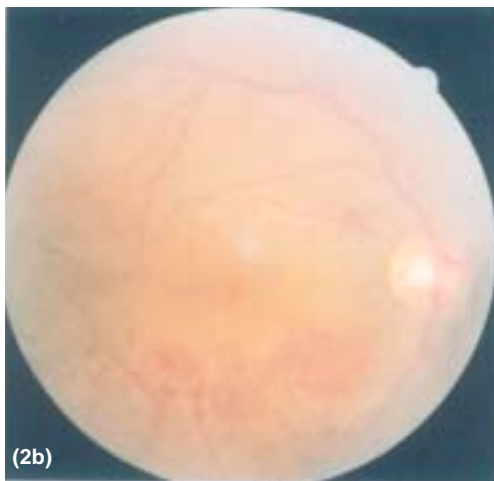


Figure 2b: 30 days following RON, clinical improvement seen as improvement of macular oedema, clearing of haemorrhages, and reduction of disc oedema. Linear scar is seen at the site of neurotomy.

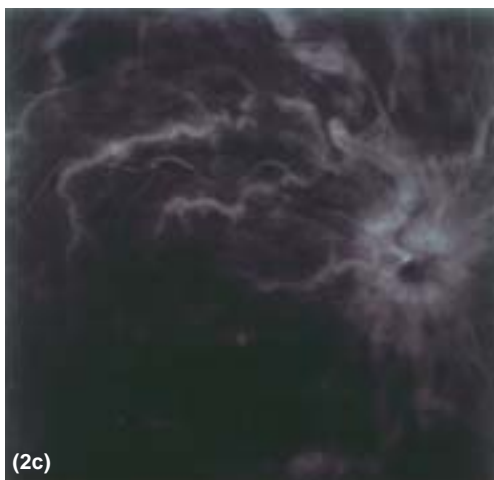

Figure 2c: Pre RON FA picture shows macular oedema, disc oedema, venous tortuosity and areas of blocked fluorescence due to haemorrhages

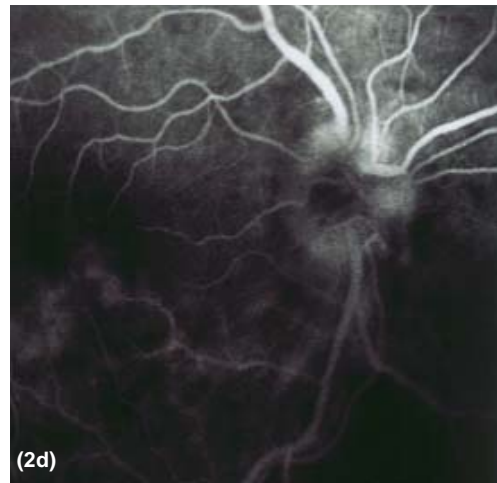


Figure 2d: Post RON FA picture showing resolution of macular oedema, disc oedema, venous tortuosity and dilatation and reduction of areas of blocked fluorescence due to haemorrhages

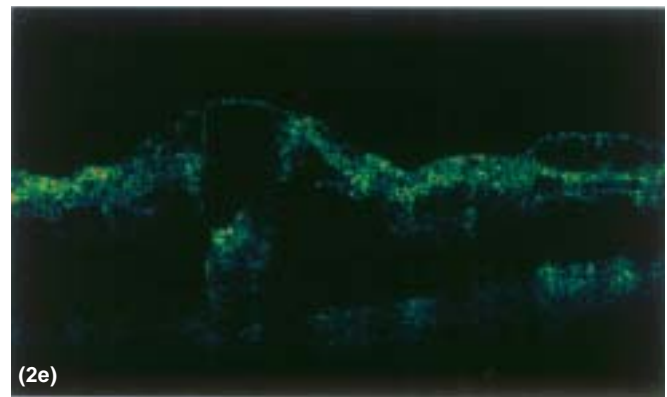


Figure 2e: Pre RON macular OCT scan

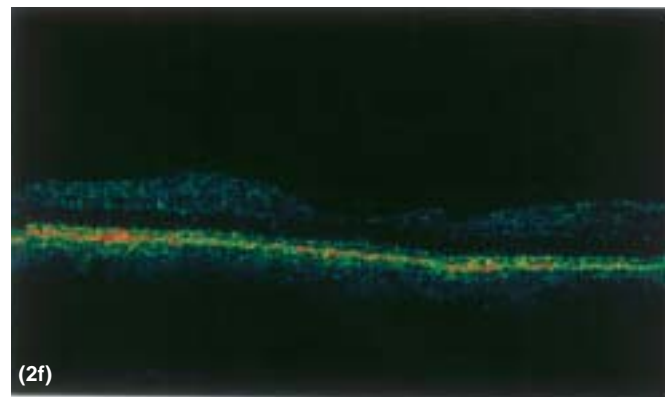


Figure 2f: Post RON macular OCT scan shows decrease in macular thickening

CRVO less than two months' duration, and exclusion of eyes with retinal neovascularisation, neovascular glaucoma, areas of capillary non-perfusion on angiography and history of previous laser photocoagulation and vitreous haemorrhage. Contrary to reports by Opermcaak *et al*⁵ (improvement of 5 lines), our patients improved an average of 3 lines; this was similar to the reports of Garcia-

Arumi, et al.⁷ In our case results were better than the natural history of CRVO.⁸

Varying but definite clinical improvement findings such as decline in macular oedema, decreased or resolved intraretinal haemorrhages, have been observed by us and previous authors.^{5,7} In our cases, no eye developed retinal neovascularisation, iris neovascularisation, or neovascular glaucoma postoperatively, unlike the high risk of developing ischaemic CRVO in the natural course in these cases.⁸

Our modified RON procedure may possibly work by a combination of different mechanisms, as discussed below.

1. Relief of mechanical pressure exerted on the central retinal vein by the distended optic nerve.⁵ This is known to improve the retinal blood flow.
2. Vitrectomy and posterior hyaloid peeling have been shown experimentally to decrease macular oedema, most probably by enhancing the exchange between the retina and the vitreous cavity.²⁴⁻²⁶
3. Passive aspiration of retinal haemorrhages and mechanical pressure and squeezing effect of PFCL.

Garcia-Arumi et al⁷ noted new chorioretinal shunt vessels in 6 of 14 patients at the site of the radial optic neurotomy, creating a new pathway of venous outflow. They suggested that collaterals formed after neurotomy were more active in draining the oedema and haemorrhages than those achieved after application of argon laser. We could not document development of such chorioretinal shunt vessels in the postoperative angiograms.

The visual fields were not assessed in our patients. This was a limitation of our study though Opremac et al⁷ did not observe any postoperative visual field defects from the radial incision on the nasal side of the optic nerve.

In conclusion, RON surgery for CRVO in eyes with vision <6/60 seems beneficial, particularly in view of the dismal natural course in these cases. Developments in techniques and technology will increase the margin of safety and efficacy of this procedure.

Due significance should be given to the fact that the optic nerve-head, a very delicate and crucial structure of the eye is being dealt with surgically. Potentially severe complications, such as laceration of major vessels, optic nerve hematoma and damage and globe perforation should always be kept in mind.

References

1. Hayreh SS, Zimmerman MB, McCarthy MJ, Podhajsky P. Systemic diseases associated with various types of retinal vein occlusion. *Am J Ophthalmol* 2001;131:61-77.
2. Hayreh SS. Classification of central retinal vein occlusion. *Ophthalmology* 1983;90:458-74.
3. Green WR, Chan CC, Hutchins GM, Terry JM. Central vein occlusion: A prospective histological study of 29 eyes in 28 cases. *Trans Am Ophthalmol Soc* 1981;89:371-422.
4. Hayreh SS. Pathogenesis of occlusion of the central retinal vessels. *Am J Ophthalmol* 1971;72:998-1011.
5. Opremac EM, Bruce RA, Lomeo MD, Ridenour CD, Letson AD, Rehmar AJ. Radial optic neurotomy for pars plana optic disc surgery for surgery for central retinal vein occlusion. *Arch Ophthalmol* 2002;120:495-9.
6. Lit ES, Tsilimbaris M, Gotzaridis ED, Amico DJ. Lamina puncture: Pars plana optic disc surgery for central retinal vein occlusion. *Arch Ophthalmol* 2002;120:495-9.
7. Garcia-Arumi J, Boixadera A, Martinez-Castillo V, Castillo R, Dou A, Corcostegui B. Chorioretinal anastomosis after radial optic neurotomy for central retinal vein occlusion. *Arch Ophthalmol* 2003;121:1385-91.
8. The central Vein Occlusion Study Group. Baseline and early natural history report; the Central vein Occlusion Study. *Arch Ophthalmol* 1993;111:1087-95.
9. The central Vein Occlusion Study Group. Natural history and clinical management of Central Retinal vein Occlusion. *Arch Ophthalmol* 1997;115:486-91.
10. Scott IU, Schein OD, West S, Bandeen-Roche K, Enger C, Folstein MF. Functional status and quality of life measurement among ophthalmic patients. *Arch Ophthalmol* 1994;112:329-35.
11. The Central Vein Occlusion Study Group. Evaluation of grid pattern photocoagulation for macular oedema in central vein Occlusion: The Central Vein Occlusion Study Group N Report. *Ophthalmology* 1995;102:1434-44.
12. Mc Allister IL, Douglas JP, Constable IJ, Yu DY. Laser-induced chorioretinal venous anastomosis for nonischemic central vein occlusion: Evaluation of the complications and their risk factors. *Am J Ophthalmol* 1998;126:219-29.
13. Fekrat S, Goldberg MF, Finkelstein D. Laser-induced chorioretinal venous anastomosis for nonischemic central or branch retinal vein occlusion. *Arch Ophthalmol* 1998;116:43-52.
14. Browning DJ, Antoszyk AN. Laser chorioretinal venous anastomosis for nonischemic central retinal vein occlusion. *Ophthalmology* 1998;105:670-7.
15. Browning DJ. Fundus photographic, fluorescein angiographic, and indocyanine green angiographic signs in successful laser chorioretinal venous anastomosis for central retinal vein occlusion. *Ophthalmology* 1999;106:2261-8.
16. Fekrat S, de Juan E Jr. Chorioretinal venous anastomosis for central retinal vein occlusion: Transvitreal veinipuncture. *Ophthalmic Surg Lasers* 1999;30:52-5.
17. Lahey JM, Fong DS, Kearney J. Intravitreal tissue plasminogen activator for acute central retinal vein occlusion. *Ophthalmic Surg Laser* 1999;30:427-34.
18. Glacet-Bernard A, Khun D, Vine AK, Oubraham H, Coscas G, Soubrane G. Treatment of recent onset central retinal vein occlusion with intravitreal tissue plasminogen activator: A pilot study. *Br J Ophthalmol* 2000;84:609-13.
19. Weiss JN. Treatment of central retinal vein occlusion by injection of tissue plasminogen activator into a retinal vein.

- Am J Ophthalmol* 1998;126:142-4.
20. Weiss JN, Byone LA. Injection of tissue plasminogen activator into a branch retinal vein in eyes with central retinal vein occlusion. *Ophthalmology* 2001;108:2249-57.
21. Vasco-Posada J. Modification of the circulation in the posterior pole of the eye. *Ann Ophthalmol* 1972;4:48-59.
22. Arciniegas A. Treatment of the occlusion of the central retinal vein by section of the posterior ring. *Am J Ophthalmol* 1984;11:1081-6.
23. Dev S, Buckley EG. Optic nerve sheath decompression for progressive central retinal vein occlusion. *Ophthalmol Surg Lasers* 1999;30:181-4.
24. Hikichi T, Konno S, Trempe CL. Role of the vitreous in central retinal vein occlusion. *Retina* 1995;15:29-33.
25. Tachi N, Hashimoto Y, Ogino N. Vitrectomy for macular edema combined with retinal vein occlusion. *Doc Ophthalmol* 1999;97:465-9.
26. Sekiryu T, Yamauchi T, Enaida H, Hara Y, Furuta M. Retina tomography after vitrectomy for macular edema of central retinal vein occlusion. *Ophthalmic Surg Lasers* 2000;31:198-202.
27. Opermcak EM, Bruce RA, Lomeo MD, Ridenour CD, Letson AD, Rehmar AJ. In reply to Bynoe LA, *Retina* 2002;22:380-1.