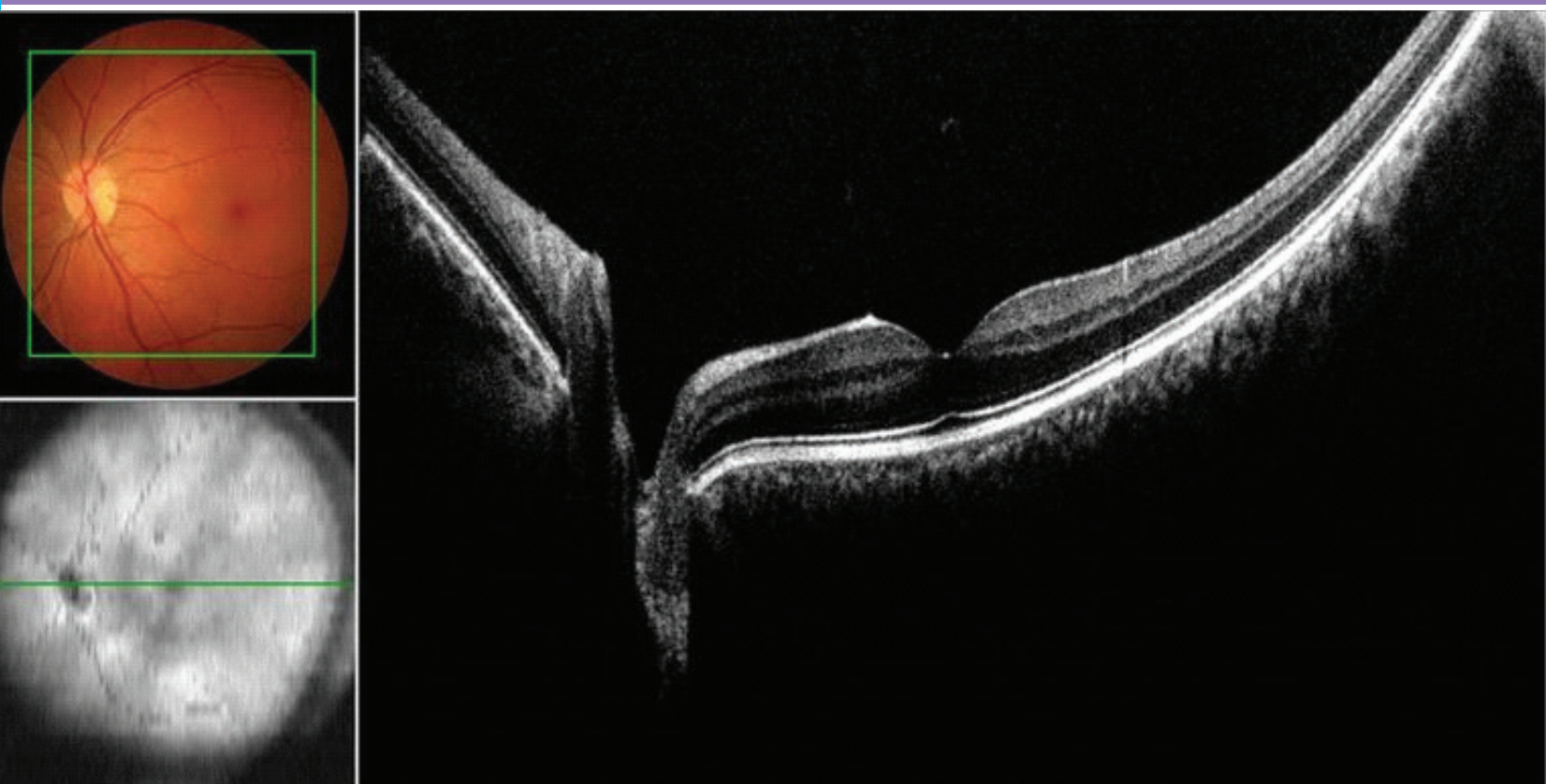


The Official Newsletter of the

VITREO RETINAL SOCIETY - INDIA

December 2017





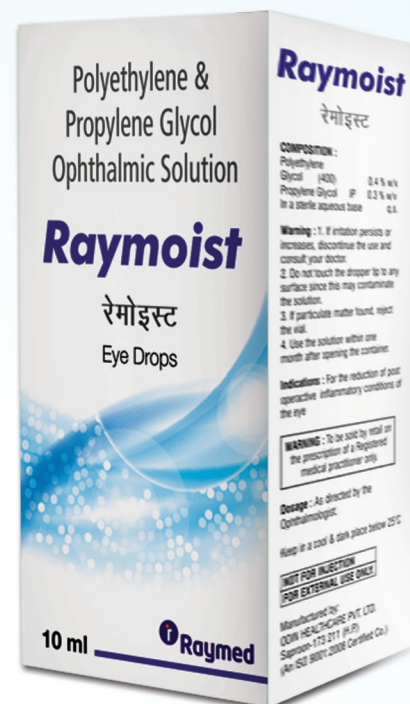moisture

*...that goes deeper, lasts long
...delivers extended protection*

Raymoist

Polyethylene glycol 0.4% w/v + Propylene glycol 0.3% w/v +
In a sterile aqueous base q.s.

Lubricant Eye Drops



Editorial Board

Editor-in-chief

Dr Vishali Gupta, MS
Chandigarh, India

Deputy Editor

Dr Anand Rajendran, MD
Madurai, India

Deputy Editor

Dr Thomas Cherian MD
Angamaly, India

Deputy Editor

Dr Ramandeep Singh MS
Chandigarh, India

Guidelines for the manuscript submission in VRSI Newsletter

Original articles:

These include randomized controlled trials, intervention studies, studies of screening and diagnostic test, outcome studies, cost effectiveness analyses, case-control series, and surveys with high response rate. The text of original articles amounting to up to 3000 words (excluding Abstract, references and Tables) should be divided into sections with the headings Abstract, Key-words, Introduction, Material and Methods, Results, Discussion, References, Tables and Figure legends.

Case reports / Challenging case /Innovations / Instruments / Techniques

New, interesting, challenging, rare cases, innovations, instruments and techniques can be reported. They should be unique and providing learning point for the readers. Manuscripts with clinical significance or implications will be given priority. These communications could be of up to 1000 words (excluding Abstract and references) and should have the following headings: Abstract (unstructured), Key-words, Introduction, Case, Discussion, Reference, Tables and Legends in that order.

The manuscript could be of up to 1000 words (excluding references and abstract) and could be supported with up to 10 references. Case Reports could be authored by up to four authors.

Mail to vishalisara@yahoo.co.in, anandrjn@gmail.com



From the President's Desk

Dr. A. Giridhar

Medical Director
Giridhar Eye Institute, Kochi
giridhareye@gmail.com

Dear Members:

Greetings!

I am extremely happy to note that the editorial board of the newsletter is releasing the 3rd and final issue of this year during the XXVI annual conference at Bhubaneswar. This issue is dedicated to the management of retinal detachment.

The purpose of the newsletter is to provide scientific information to all members which will enhance quality of the day-to-day vitreo retinal practice. Simultaneously it will provide a platform for all members to share some of their experiences and innovation. At a time when scientific information is available at the press of a button, we need to analyse as to how we can keep the newsletter relevant, informative and readable for our members.

By publishing three issues this year the editorial board has shown positive signal that the newsletter is now going to be a regular feature of the VRS-I. It is now the responsibility of all members to show some enthusiasm so that in the coming years the newsletter will grow into a journal of vitreo retinal diseases from the Indian sub-continent.

Hope you will enjoy reading this issue,

With best wishes for the New Year



From the Honorary Secretary's Desk

Dr. Raja Narayanan

Director-Head, Clinical Research Consultant,
Smt. Kanuri Santhamma Centre for Vitreo Retinal Diseases
Kallam Anji Reddy Campus, Hyderabad
narayanan@lvpei.org

Dear Friends:

Season's greetings from VRSI. I hope you had a great learning experience at our annual conference at Bhubaneswar. The editorial team lead by Prof. Vishali Gupta has worked hard to bring out this issue with latest updates in the world of retina. I look forward to your active contribution in the future editions of our Newsletter. Happy new year 2018.

Regards

Dr. Raja Narayanan

Hon. Secy, VRSI



From the Convenor Scientific Committee Desk

Dr. Vishali Gupta MD

Professor (Retina, Vitreous and Uvea)
Advanced Eye Centre,
Post Graduate Institute of Medical Education
and Research, Chandigarh-India- 160012
Tel: +91-172-2747837 FAX: +91-172-2747837
email: vishalisara@yahoo.com
vishalisara@gmail.com

Dear Members:

Greetings from the Vitreo Retinal Society-India!

It gives me immense pleasure in bringing out the third Newsletter by VRSI for the year 2017. Following the last Newsletter on OCT Angio, we decided to switch gears and change the theme to Vitreo-retina Surgery. This issue involves the write-ups by the world-renowned Vitreoretina surgeons who have put up their experiences eloquently to pass on the experience to next generation.

The editorial team of VRSI is working hard to bring out the quality newsletters three times a year to the members and I do hope that all of you are enjoying reading it. I would like to place a special thanks to Dr Ramandeep Singh for being instrumental in taking out these newsletters on time.

Beyond but before the vitreoretinal surgery

Amod Gupta
Emeritus Professor,
Post Graduate Institute of Medical Education and Research, Chandigarh
dramodgupta@gmail.com

Many years ago, Robert Sommers defined 'Personal space' as the physical space immediately surrounding someone. It is a private invisible bubble that surrounds a person. Generally, it is taken as 4 feet for strangers and less for the family and the friends. This space may vary in different cultures and societies. A number of unwritten rules and etiquettes dictate how to maintain the sanctity of this space. Irrespective of the cultures, the basic principle is not to touch the person.

I am sure, by now, most of you, the vitreoretinal surgeons, are wondering how this elaborate definition of personal space is relevant to your practice. So, my readers, I am writing this piece specifically for all of you who wished to quit after reading the first para.

Invasion of personal space and loss of autonomy: You would have realized by now that I am not going to give you an insight into the fine nuances of vitreoretinal surgery, which as members of this august society you would all be very familiar. Coming back to the subject of personal space, did you ever realize what happens when you invade or encroach upon this space? The person feels violated and threatened to lose autonomy. Autonomy is freedom to make choices. As Julius Fast said in his book 'Body Language', when you violate the personal space of a person, you are conveying to him "You are a non-person, you do not matter".

Can anyone violate this space? None without consent. As a matter of fact, even for shaking hands you need to have the assent or consent of the other party. Yet, who violates this space with impunity? No guesses here. Yes, it is the physicians who violate this space day in and day out. Why do you think they do it? For several generations, we have lived the idiom "Doctor knows the best" implying that we as physicians alone know what is in the best interest of the patient, ignoring the patient's freedom of making a choice for her own well-being.

Importantly, in a World Medical Association meeting in Chicago in October 2017, Declaration of Geneva was revised to include 'Respect for autonomy and dignity of my patient' at the second place in the Modern-Day Physician's pledge. (JAMA published online on Oct. 14, 2017).

Assent vs. Consent: Let me elaborate on this. There is a fine distinction between the two. Assent is an agreement or willingness, even a nod may express willingness but it does not have legal sanction. I shall illustrate with an example you can all relate. A patient walks into your clinic. You ask him, and I sincerely hope to God that you do ask, "May I examine you?" He nods (her assent) and you proceed to examine her. I am sure you all can recall the time, as the patient walked into your room, suddenly you became the owner of the body or the body parts to do whatever you wished to do with it including cutting it open if you please. Please note that just because she is present at your clinic or the hospital does not mean that she has agreed/consented to follow your advice, treatment or interventions. Respect for patient's autonomy is a basic tenet of medical ethics while autonomy by a competent adult is a basic principle of jurisprudence.

A basic principle of decision making and legal consent: We have to understand the patient has the legal and ethical right to participate in decision making of her treatment. Moreover, every physician has an ethical duty to inform the patient what he is going to do. Legal informed consent can be given by a competent adult only after she has understood the reason, the benefits, the risks and reasonable alternatives, if any, to the treatment being offered to her. Generally, invasive procedures that involve anaesthesia or surgery require written informed consent.

Counselling: Counselling is a process of interaction between the

patient and her physician to obtain an informed consent. You have to realize that the patients are under stress, they are anxious and fearful. They may be totally blanked out as you break the news of a disease or the need for a procedure or an urgent surgery. It is very important, therefore, to assess the patient's ability to comprehend what you are talking. It is important to record that patient has understood her condition and was able to comprehend and understand the discussion that followed. If you feel that the patient is not competent (say a child) or is not able to comprehend, you must seek a surrogate decision maker. Having understood the condition and its implications, but refusing to follow your advice should not mark the end of the dialogue and she must be encouraged to continue the discussion on another visit.

Who should do the counseling? On entering a physician's clinic, patients, especially from the lower socio-economic background and rural areas, may get overwhelmed by the glamour of your clinic, your name, and fame. They may not feel comfortable asking the questions they need to ask. They may feel compelled to give you the consent for any procedures you wish to do. Under these circumstances, the Aravind Eye Care System, Madurai have found a novel way to use trained counselors who belong to the same geographical area, speak the same language and belong to the same social background to counsel, inform and address all the apprehensions and fears. On the other hand, this strategy may not work with highly informed patients who may like to address their questions directly to the physician.

How much to inform: Typically surgeons inform very little. But it is important to inform only as much the patient can easily understand without getting overwhelmed by the quantum of information. There are no set standards. It shall depend on the patient's ability to comprehend. Generally, it shall be governed by a simple principle of what a reasonable doctor under similar circumstances would like the patient to know and what a reasonable patient would expect his doctor to inform. When choices exist, the patient must be told of the most conservative strategy as in the event of a complication arising out of a more aggressive or expensive procedure, it is likely to be held against the physician. Many of your patients are internet savvy and may have their questions. As a principle, never shut a patient even if the questions may be irrelevant. As a vitreoretinal surgeon, you have an advantage over other physicians, of using your computer screen to demonstrate to the patient what is wrong, whether his sight is threatened and how he is progressing following an intervention. You should never underestimate the capacity of patients, Irrespective of the literacy levels, to understand what is wrong with their eyes. I have been highly impressed the way the

digital images in recent years have revolutionized our communications with the patient. Go ahead and exploit it to its full potential.

You must aim to avoid surprise outcomes. Ideally, have a witness to your discussion. It is hardly surprising that unsatisfied patients have a very short memory. From the way a patient communicates, "I can't remember you ever telling me this" to "I am not satisfied" or "I have lost trust in you", you know charges of negligence are on your way. Written documents recording your discussion with the patient witnessed by a third party would come to your rescue.

Dos and Don'ts of counseling: Do not use medical jargon. Patient must understand in his own language what you plan to do. Remember it is not a monologue, but an interaction. The counselor must ask from time to time if she understands the implications. Some of the essentials of communication skills that need to inculcate in your demeanor include minding your own body language, the art of listening, not looking distracted and making frequent eye contact and not staring. Emphasize information and not consent. At the end of the discussion, your recommendation should be based on your own experience and expertise. The patient must say that he shall undergo the procedure of her own free choice.

Elements of ethical care: I believe there are 5 basic elements of ethical care. Care you provide must be effective, efficient, equitable, economical and empathetic. Is the treatment you are offering effective? Does it really work? Is it evidence-based? Is it based on your clinical sense? Are you providing care efficiently? Is it timely? Is it fair and honest? Do you select your patients based on socio-economic considerations? Is the care cost-effective? Do you believe that more expensive treatment is more effective?

Finally, I urge you to keep the well-being of your patients as your first and the most important consideration while maintaining the utmost respect for human life and practice your profession with conscience and dignity aligned with good medical practices.

Innovations in Vitreoretinal Surgery: Novel Viewing Technology in Surgeon Education

Himanshu K. Banda, MD

Gaurav K. Shah, MD

The Retina Institute, St. Louis, Missouri

1600 S. Brentwood Blvd., Suite 800

St. Louis, MO 63144

(314) 367 1181

Abstract

This article describes the utility of a novel viewing technology in vitreoretinal surgery. We focus on two digitally assisted viewing systems: intraoperative optical coherence tomography (OCT), and three-dimensional (3D) visualization platforms.

Introduction

For training surgeons, tools in developing intraoperative technique and decision making are using virtual training devices prior to the operating room, and viewing recordings of procedures post hoc^{1,2}. Both practices allow novice surgeons to observe and critique skills in a low-stakes environment, building comprehension of surgical skills. However, there have been few advances in enhancing the intraoperative viewing experience for training surgeons.

When performing surgery under a conventional operating microscope, the surgeon is limited to an en face view, and axial information is inferred from indirect cues³. Though suffice for a skilled surgeon, training surgeons may benefit from enhanced feedback. We describe two digitally assisted viewing systems, intraoperative OCT and 3D surgery, and their roles in vitreoretinal surgical training.

Intraoperative OCT:

Spectral domain (SD) OCT is a noninvasive method for imaging tissues, and has dramatically transformed diagnosis and management of several retinal diseases⁴. Its use intraoperatively has been described in multiple types of vitreoretinal surgery, including vitrectomy for macular hole, vitreomacular traction, subretinal tissue plasminogen injection for submacular hemorrhage and retinal detachment⁵⁻⁸.

Similar to OCTs used in office, intraoperative OCT acquires A-scans images which can be reviewed by the surgeon on an external display monitor or displayed through the microscope field. Current models developed include Carl Zeiss Meditac Rescan 700 ICT system, which is a real-time intraoperative SD-OCT integrated with an OPMI Lumera 700 microscope and Haag-Streit's intraoperative iOCT system, developed by OptoMedical Technologies. Bioptigen (parent company Leica Microsystems) has developed the Envisu C2300 Spectral Domain Ophthalmic System for handheld use and the EnFocus™ (Figure 1) for microscope-mounted use. Both Bioptigen systems are approved in the United States for intraoperative use.

Intraoperative OCT may change the educational environment and learning-curve by adding feedback on tissue anatomy in real time. A 2-year investigational study performed on intraoperative handheld OCT devices on the market have demonstrated valuable feedback that may alter surgical decision-making⁹. Another study was performed using the RESCAN 700 device¹⁰. The authors reported the most common reason for altering a procedure was discordance between the surgeon's subjective impression of peel completion and objective intraoperative OCT findings.

3D Viewing System

Three-dimensional monitoring has been well implemented in various applications. The term "heads-up surgery" derives from "heads up display," which is a system used in aircraft flight decks allowing pilots to view images in a heads-up position. Variations of this technology are now used military training and entertainment, including cinema and video games¹¹. "Heads-up display" systems have recently arrived in medical use, implemented in surgical fields such as urologic and laparoscopic surgery¹². For intraocular surgery, studies have suggested that it is

well suited for vitreoretinal surgery¹³.

Alcon Laboratories, in collaboration with TrueVision® 3D Surgical (TrueVision Systems, Inc, Santa Barbara, California), has designed Ngenuity®, an ocular-free visualization system for digitally assisted vitreoretinal surgery (Figure 2). The system utilizes a display which separates visual information between each eye. Combined with polarized 3D glasses, which are worn during cases, a 3D experience is visualized on a high definition screen. "Head-mounted display systems" (HMS) near the end of the bed to allow a "heads-up" experience (Figure 3). Sony (Sony Electronics, Inc, Tokyo, Japan) has developed the HMS-3000MT®, a personal viewing system providing 3D color video display images from 3D surgical camera systems. Head sets are available for the primary and assistant surgeon.

3D systems are being adopted at training sites for both anterior and posterior segment surgery. There are multiple advantages using an ocular-free viewing system. Active observation is critical in transferring skills from mentor to trainee in the operative room¹⁴. For a novice surgeon, being able to translate verbal instructions into a surgical maneuver can be challenging. While operating with a 3D viewing platform, some instructors project a laser pointer on the display screen to identify anatomical landmarks. This reduces ambiguity and visualization discrepancies between the instructor and trainee. Survey studies assessing skill comprehension of training vitreoretinal surgeons indicated those using a 3D viewing system scored higher than trainees using a standard microscope system.¹⁵

Conclusion:

For ophthalmic surgical training, investigating ways to optimize precision in skill-transfer while reducing iatrogenic trauma and visual morbidities is an active concentration of investigation^{16,17}. Prospective trials have indicated that virtual simulation models supplement surgical skills training, and even reduce intraoperative error by trainees^{18,19}. Such "VR to OR" studies investigate how surgeon skills can be developed prior to real-time surgery. Virtually assisted viewing systems, such as intraoperative OCT and 3D surgical displays, are ways to enhance feedback during the surgical experience. Though more studies need to be performed using novel viewing technology in-vivo, there certainly appears to be a role in supplementing trainee education.

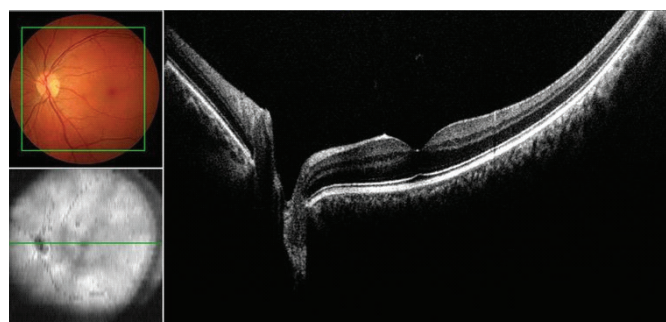


Figure 1: Display of intraoperative OCT, with InVivoVue™ software²⁰

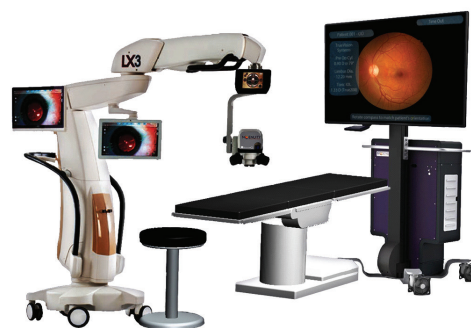

Figure 2: 3D Surgical display demonstrating microscope camera and high definition display (image provided by Novartis, NGENUITY® Media Release²¹).

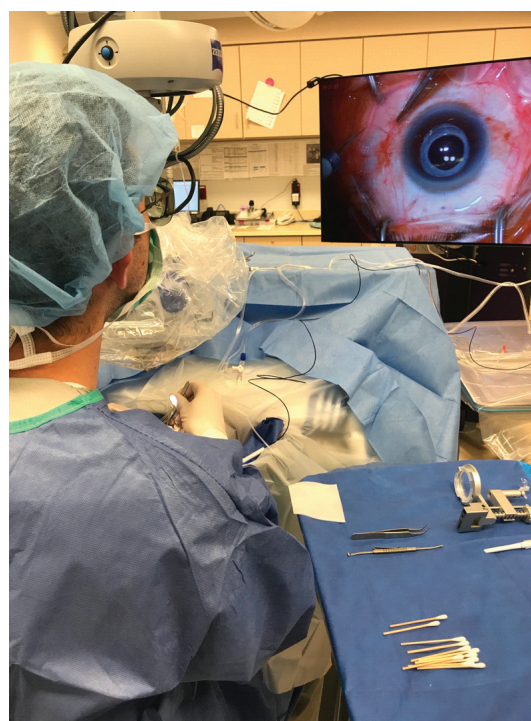

Figure 3: "Heads-up surgery" using the image on a display positioning at the head of the patient's bed. Microscope oculars are replaced for a 3D camera.

References

1. Satava RM. Virtual reality surgical simulator. The first steps. *Surg Endosc* 1993;7:203-5.
2. Steedman M, Abouammoh M, Sharma S. Multimedia learning tools for teaching undergraduate ophthalmology: results of a randomized clinical study. *Can J Ophthalmol* 2012;47:66-71.
3. Carrasco-Zevallos OM, Keller B, Viehland C, et al. Optical Coherence Tomography for Retinal Surgery: Perioperative Analysis to Real-Time Four-Dimensional Image-Guided Surgery. *Invest Ophthalmol Vis Sci* 2016;57:OCT37-50.
4. Huang D, Swanson EA, Lin CP, et al. Optical coherence tomography. *Science* 1991;254:1178-81.
5. Ehlers JP, Ohr MP, Kaiser PK, Srivastava SK. Novel microarchitectural dynamics in rhegmatogenous retinal detachments identified with intraoperative optical coherence tomography. *Retina* 2013;33:1428-34.
6. Ehlers JP, Petkovsek DS, Yuan A, Singh RP, Srivastava SK. Intrasurgical assessment of subretinal tPA injection for submacular hemorrhage in the PIONEER study utilizing intraoperative OCT. *Ophthalmic Surg Lasers Imaging Retina* 2015;46:327-32.
7. Ehlers JP, Xu D, Kaiser PK, Singh RP, Srivastava SK. Intrasurgical dynamics of macular hole surgery: an assessment of surgery-induced ultrastructural alterations with intraoperative optical coherence tomography. *Retina* 2014;34:213-21.
8. Dayani PN, Maldonado R, Farsiu S, Toth CA. Intraoperative use of handheld spectral domain optical coherence tomography imaging in macular surgery. *Retina* 2009;29:1457-68.
9. Ehlers JP, Dupps WJ, Kaiser PK, et al. The Prospective Intraoperative and Perioperative Ophthalmic Imaging with Optical Coherence Tomography (PIONEER) Study: 2-year results. *Am J Ophthalmol* 2014;158:999-1007.
10. Runkle A, Srivastava SK, Ehlers JP. Microscope-Integrated OCT Feasibility and Utility With the EnFocus System in the DISCOVER Study. *Ophthalmic Surg Lasers Imaging Retina* 2017;48:216-22.
11. Wanibuchi M, Komatsu K, Akiyama Y, Mikami T, Mikuni N. Effectiveness of the 3D Monitor System for Medical Education During Neurosurgical Operation. *World Neurosurg* 2017.
12. Curro G, La Malfa G, Caizzone A, Rampulla V, Navarra G. Three-Dimensional (3D) Versus Two-Dimensional (2D) Laparoscopic Bariatric Surgery: a Single-Surgeon Prospective Randomized Comparative Study. *Obes Surg* 2015;25:2120-4.
13. Eckardt C, Paulo EB. HEADS-UP SURGERY FOR VITREORETINAL PROCEDURES: An Experimental and Clinical Study. *Retina* 2016;36:137-47.
14. Reznick RK, MacRae H. Teaching surgical skills--changes in the wind. *N Engl J Med* 2006;355:2664-9.
15. Chhaya N, Helmy O, Piri N, Palacio A, Schaal S. Comparison of 2d and 3d Video Displays for Teaching Vitreoretinal Surgery. *Retina* 2017.
16. Beard JD, Marriott J, Purdie H, Crossley J. Assessing the surgical skills of trainees in the operating theatre: a prospective observational study of the methodology. *Health Technol Assess* 2011;15:i-xxi, 1-162.
17. Taravella MJ, Davidson R, Erlanger M, Guiton G, Gregory D. Characterizing the learning curve in phacoemulsification. *J Cataract Refract Surg* 2011;37:1069-75.
18. Seymour NE, Gallagher AG, Roman SA, et al. Virtual reality training improves operating room performance: results of a randomized, double-blinded study. *Ann Surg* 2002;236:458-63; discussion 63-4.
19. Grantcharov TP, Kristiansen VB, Bendix J, Bardram L, Rosenberg J, Funch-Jensen P. Randomized clinical trial of virtual reality simulation for laparoscopic skills training. *Br J Surg* 2004;91:146-50.
20. InVivoVue™ Software Simplifies the Workflow. at https://www.leica-microsystems.com/products/optical-coherence-tomography-oct/details/product/enfocus/?nlc=20140326-DEWE-9HKLQA&utm_source=ScienceLab&utm_medium=Article&utm_campaign=EnFocus2017
21. NOVARTIS. Alcon launches the NGENUITY® 3D Visualization System designed to further enhance retinal surgeon experience. 2016.

PPV for Giant Retinal Tears – Tips and tricks

Dr. P. Mahesh Shanmugam, DO, FRCSEd, PhD,
FAICO Dr. Pradeep Sagar, MD.

Department of vitreoretinal and
ocular oncology services, Sankara Eye Hospitals, India

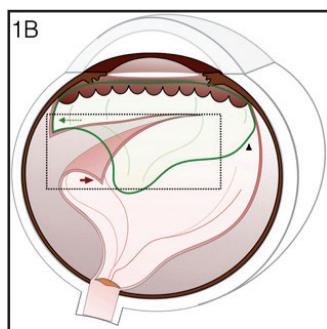
Vitrectomy for giant retinal tear can yield extremely gratifying anatomical and visual results, though the surgery itself can be a challenge at times. Let us look at the salient features of pars plana vitrectomy in giant retinal tears (GRT).

Relevant pathoanatomy:

In giant retinal tears, the retina tears at the posterior border of the vitreous attachment at the vitreous base.

Relevance:

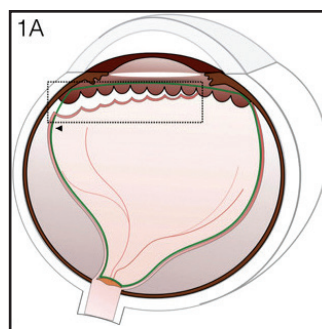
- There is always a posterior vitreous detachment in GRT.
- There is always an anterior retinal flap in a GRT.
- The detached vitreous is attached to the anterior flap of the tear (Figure 1B).



1B: Giant retinal tear. There is always a posterior vitreous detachment in GRT (black arrow head). There is always an anterior retinal flap in a GRT and detached vitreous is attached to the flap (green arrow). The free posterior edge of the tear rolls back (red arrow).

- As the vitreous is displaced anteriorly, there is inadequate vitreous to tamponade the tear, if one were to attempt scleral buckling. This also results in free movement of the GRT and thereby gaping of the tear in the absence of an internal tamponade.
- In a giant retinal dialysis, the tear is at the ora serrate with the

vitreous remaining attached up to the edge of the tear. Hence there is no anterior flap, there is vitreous to internally tamponade the dialysis if one were to attempt a buckle. (Figure 1A).



1A: Giant retinal dialysis. The tear is at the ora serrata (within the rectangle). The vitreous remains attached up to the edge of the tear (black arrow head).

Choice of Surgery - Vitrectomy or Scleral Buckling

Scleral buckling can be attempted in select GRT's

- Superior GRT's with no or shallow retinal detachment wherein a scleral buckling combined with pneumoretinopexy can be attempted.
- GRT's without rolled edges, around 900 in extent and not freely moving with eye movement.

A broader than usual buckle with an encircage is preferred. Careful cryotherapy, sparing the bare retinal pigment epithelium (RPE) will minimize subsequent PVR.

In all other situations, a vitrectomy is the surgery of choice in GRT.

Tackling the lens

Most often lens removal is not necessary. However a thick lens as in nuclear sclerosis may not allow access to the anterior flap of the GRT. Attempting to remove the anterior flap 180° away from the active sclerotomy can result in a lens touch (Figure 2).

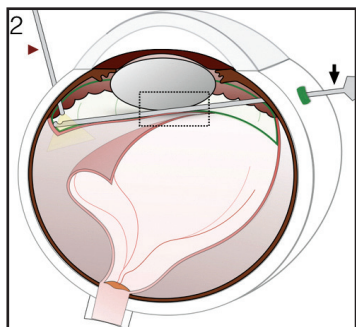


Figure 2: Attempting to remove the anterior flap 180° away from the active sclerotomy with the cutter (black arrow) results in lens touch (indicated within the rectangle).

Hence, in patients where such an eventuality is anticipated, vitrectomy can be combined with a phacoemulsification. I usually do plan to place the intraocular lens (IOL) by a subsequent surgery and it is up to the surgeon's personal preference. An intraocular lens has the benefit of stretching the capsular bag, thereby avoiding accidental damage during anterior vitrectomy. The negatives in placing an IOL during the primary surgery are the difficulty in assessing the correct IOL power in the presence of a detached macula/ placement of an encercage and managing the IOL in the event of a recurrent retinal detachment.

Accessing the anterior flap with the lens in place can at times be a challenge. A careful scleral depression by the surgeon himself using cotton tipped applicator, will allow removal of the anterior flap (Figure 3A). The cotton tipped applicator does not slip and hence offers a controlled depression. Holding the vitrector in other hand to access the vitreous base on the same side (thus not crossing the posterior pole of the lens) will decrease the risk of iatrogenic lens damage (Figure 3B).

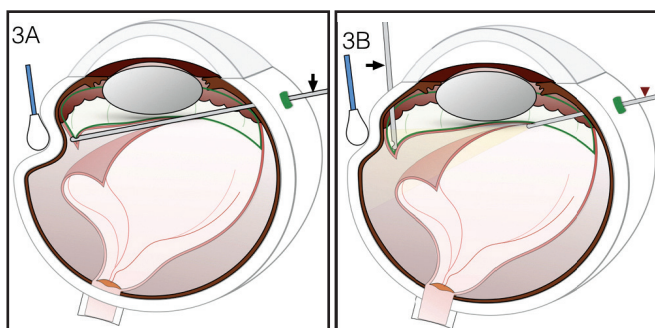


Figure 3: Avoiding lens touch.

3A: A careful scleral depression by the surgeon himself using cotton tipped applicator, will allow removal of the anterior flap. Cutter is indicated by black arrow. 3B: Vitrectomy cutter (black arrow) is used to access the vitreous base on the same side to prevent iatrogenic lens damage.

Encercage or no encercage

In some limited GRT's one can see the tear extend during vitrectomy and also the strong traction being exerted by the vitreous base in areas distant from the tear. It is impossible to relieve the vitreoretinal traction completely in these eyes – attempting the same extends the tear. In such eyes, the rest of the vitreous base can be supported with an encercage. An encercage is otherwise not routinely required in GRT vitrectomy.

Vitrectomy

Presence of posterior vitreous detachment makes vitrectomy easy. A thorough excision of the vitreous base is essential.

In GRT complicated by PVR, bimanual surgery aided by chandelier illumination is preferable.

Anterior flap management

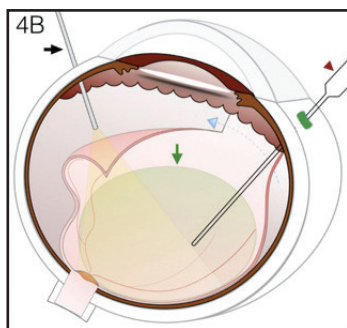
The anterior flap of the GRT may adhere to the ciliary process and the resultant proliferation may extend circumferentially resulting in subsequent hypotony. Hence it is preferable to excise the same. In select situations wherein the anterior flap is not contracted and attaches after perfluorocarbon liquid instillation or fluid gas exchange, the anterior flap can be tethered to the RPE with laser photocoagulation.

Edge of the GRT

The GRT edge may be rolled because of PVR. As it is difficult to dissect the PVR off the edge, the rolled edge is cauterized. Cauterization of the edge decreases the risk of bleeding from the edge and results in necrosis of the PVR involving the GRT edge. Excision of this edge is necessary if the edge remains rolled under PFCL.

Reattachment of the retina

The retina is reattached using perfluorocarbon liquid (PFCL), which is instilled slowly over the disc. Rolling the eye away from the GRT during injection of the PFCL will flatten the retina away from the GRT thereby pushing subretinal fluid towards the GRT, thus avoiding trapped fluid (Figure 4B).



4B: The eyeball is rolled away from the GRT during injection of the PFCL (black arrow). This will flatten the retina away from the GRT and pushes subretinal fluid towards the GRT (blue dashed arrow).

The PFCL is preferably placed up to the sclerotomy or at least beyond the GRT thereby preventing seepage of fluid beneath the retina (Figure 5).

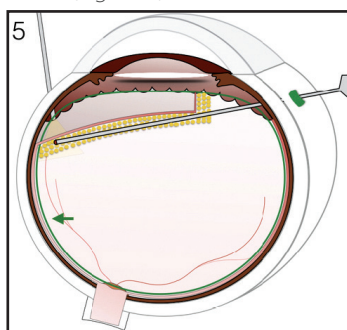
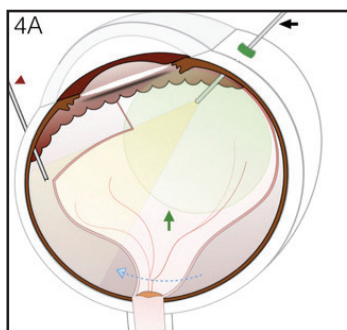


Figure 5: PFCL is placed up to the sclerotomy or at least beyond the GRT (black arrow indicates PFCL). Treat the GRT margin with 2-3 rows of contiguous laser photocoagulation and this should extend up to the ora serrata at the edges of the GRT.

In small GRT's associated with limited retinal detachment, it may be possible to attach the retina with fluid air exchange. If reattaching the retina with fluid air exchange, the eye is rolled towards the GRT thereby allowing the air to float up to the quadrant opposite the GRT, thus pushing the fluid towards the GRT (Figure 4A).



4A: In small GRT, the eye is rolled towards the GRT thereby allowing the air (black arrow) to float up to the quadrant opposite the GRT, thus pushing the fluid towards the GRT (blue dashed arrow) and simultaneous aspiration of SRF with flute needle (red arrow head).

Retinopexy

It is preferable to treat the GRT margin with 2-3 rows of

contiguous laser photocoagulation and this should extend up to the ora serrata at the edges of the GRT (Figure 5). While it may be difficult to laser anteriorly, performing laser under the PFCL ensures adequate visualization of the edge close to the ora also aided by the assistant depressing the requisite area.

In eyes wherein this is difficult, laser photocoagulation of the edges can be completed using the laser indirect ophthalmoscope. While it is tempting to treat the edges with cryopexy, it is best avoided to decrease the risk of PVR. If at all cryo is to be done, it can be limited only to the ora edge of the GRT, the other areas being treated with laser photocoagulation.

Laser photocoagulation 3600 to the vitreous base region other than the area of the GRT can also be considered, particularly if one notices strong vitreoretinal adhesion at the vitreous base. However, this is not necessary if the vitreous is detached up to the ora in areas away from the GRT. It is also not preferable to do extensive laser if an encircage has been placed. A combination of the encircage and extensive laser photocoagulation appears to increase anterior retinal ischemia resulting in subsequent anterior hyaloid proliferation and hypotony.

Tamponade

Most often silicone oil tamponade is the preferred tamponade in GRT cases. A direct PFCL silicone oil exchange can be done, the silicone oil being infused through the infusion cannula. The limitations of injecting the oil through the infusion cannula is that the combination of small bore of the tube and its length increases the resistance to flow of oil, thereby increasing the intraluminal pressure within the infusion cannula tubing. This can result in the tubing disengaging from the syringe or from the eye. The lubricating effect of the oil also makes it difficult to secure the tubing again. The tubing has to be cleaned thoroughly after using it to inject silicone oil or it may result in inadvertent silicone oil bubbles being injected in to the vitreous cavity of the subsequent patient in whom the infusion cannula is used. This will result in the patient complaining of silicone oil floaters.

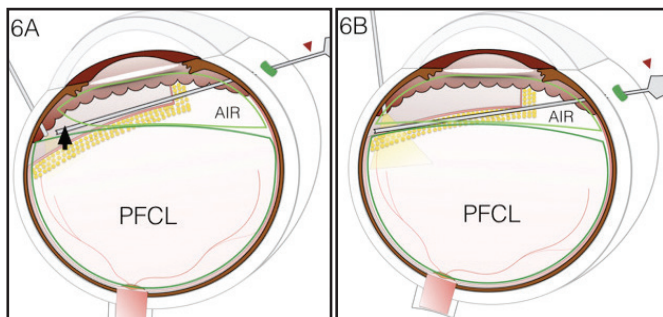
Alternately PFCL air exchange can be done followed by air silicone oil injection. The advantage of this technique is that oil injection via the infusion cannula is avoided, the oil being injected through one of the superior cannula directly in to the vitreous cavity

Slippage of the GRT

Slippage of the GRT is a concern with either of the techniques. Slippage occurs as the fluid trapped between the PFCL and

silicone oil/ air slips beneath the GRT edge. Preferred technique to avoid slippage is as follows:

Oil/ air is allowed to fill the anterior vitreous and the wide angle imaging system is refocused. Once a clear fundus view is obtained, the eye is rolled towards the GRT and the flute needle is kept at the periphery, between the two bubbles, removing the fluid trapped between the two convex bubbles (Figure 6A). Gently dipping in to the PFCL, the PFCL bubble is allowed to retract until the posterior most edge of the GRT (Figure 6B). It is preferable to keep the flute at the edge of the GRT, partly engaging the GRT edge. This will aid further drainage of the fluid between the bubbles and also any trapped subretinal fluid. Keeping the eye rolled so that the GRT edge is dependent will facilitate drainage of the fluid that is heavier than the silicone oil / air and also the heavier PFCL, both of which track towards the flute.



6A: The eye is rolled towards the GRT and the flute needle is kept at the periphery, between the two bubbles, removing the fluid trapped between the two convex bubbles (black arrow). 6B: Gently dipping in to the PFCL, the PFCL bubble is allowed to retract until the posterior most edge of the GRT.

Once the silicone oil/ air has crossed the GRT edge, the flute can be moved towards the retracting PFCL bubble, keeping the flute at the edge of the bubble and not within it, this also aiding in removing any minimal residual fluid and minimizing the chance of slippage. Moving the flute posteriorly, following the retracting PFCL bubble will allow complete removal of the PFCL.

Completion of the exchange is when the final bubble of PFCL is aspirated from the optic disc region. Removal of the last PFCL bubble is distinctly seen when exchanging silicone oil directly with the PFCL. This may however be difficult when performing air PFCL exchange as the PFCL is spread thin over the retinal surface by the expanding air bubble, resulting in some PFCL to remain over the macular region (the most dependent portion)

In the event slippage of the tear occurs, it can be countered as below:

- A small circumferential fold that is away from the macular region can be left alone – post-operative prone position can result in ironing out of the fold.
- Multiple folds not involving the macula can be tackled by gently stretching the retina by engaging it in the tip of the flute needle and dragging it towards the ora. The elevated IOP due to injection of air/ silicone oil facilitates engagement of the GRT edge in to the flute tip. Minimally elevating the GRT edge and dragging it towards the ora, keeping the flute close to the RPE will allow removal of the trapped subretinal fluid and also mechanically iron out the folds.
- In case of a major slippage, extending in to the macula, it may be necessary to remove the oil, and repeat the exchange all over.

In eyes with GRT complicated by PVR, the folds may not iron out completely due to intrinsic contraction of the retina, despite removal of all membranes. In such cases, retaining PFCL as tamponade for 1-2 weeks and replacing it with silicone oil can help stretch the retina and iron out the folds. In select cases where further tamponade is not needed, PFCL removal, replacing it with balanced salt solution can be done as well.

In superior GRT's gas tamponade in lieu of silicone oil is adequate, particularly if it is a small GRT or in those in which an additional encroachment has been used.

Post-operative position

Immediate continuous prone positioning will aid flattening of a minor circumferential retinal fold due to minor slippage.

Surgery For ROP - Current Practice Patterns

Author: Lingam Gopal

Affiliation: Medical Research foundation; Chennai

National university hospital; Singapore

Date of submission: 23rd October 2017

Address for correspondence: Lingam Gopal; Sankara Nethralaya;
18 college road; Chennai; 600017

E mail: drlg@snmail.org; lingamgopal@hotmail.com

Retinopathy of prematurity (ROP) is a condition that affects infants born premature and of low birth weight. While the first stage is one of avascular retina, it is the proliferative stage that leads to vision threatening complications.⁽¹⁾ The standard of care involves screening the infants at risk at the appropriate time to detect ROP; identify pre threshold ROP that may need intervention; perform laser photocoagulation and follow the patient with periodic examinations till the entire retina is normally vascularized. ROP has been divided into 5 stages of which stages 4 and 5 involves traction component caused by fibrotic organization of the vitreous that detaches the retina.⁽²⁾ Surgery as an option is considered for stages 4 and 5. In this brief article the indications, approach and outcome of surgical management of ROP will be discussed.

Pathology

Retinal detachment caused by ROP is to start with, always tractional although some exudative component can be contributing to the amount of sub retinal fluid. A predominantly exudative retinal detachment is relatively rare and is characterized by a convex surface of retinal detachment. In the initial stages of ROP (stages 1-3), all the changes are in the retina characterized by avascular peripheral retina with a sharp demarcation between posterior normally vascularized retina and anterior avascular retina in stage 1; a sharp ridge of elevated tissue at the same location in stage 2; and fibro vascular proliferation that penetrates the internal limiting membrane in stage 3. Subsequently the vitreous undergoes various degrees of fibrosis that leads to the tractional component being added to the disease process. The origin of the fibrosis is usually the original ridge area and hence the tractional retinal detachment also originates in the same area.⁽³⁾ Once initiated it can spread posteriorly and anteriorly. Atypical form of fibrovascular

proliferation is seen sometimes in severe posterior ROP wherein the fibro vascular proliferation is mainly from the optic disc ⁽⁴⁾. Diffuse contracture of the posterior hyaloid can also occur leading to severe distortion of the retinal surface. In the absence of vitreous detachment, the fibrovascular organization of the posterior hyaloid binds to the retina firmly making it sometimes difficult to easily identify the retina apart from the fibrous tissue.⁽⁵⁾

The vitreous undergoes synerisis to a variable extent. Advanced cases present with retrolental fibroplasia- the retina is thrown into intricate folds with the fibrous tissue filling the spaces or bridging the folds. The peripheral avascular retina tends to remain attached, thus creating a sharp trough in the periphery. The width and depth of this trough can vary depending on the original location of the ROP.

Other changes that influence the surgical anatomy

(a) Duration of the retinal detachment: The detached retina becomes thin and atrophic in relatively long standing retinal detachments making it more difficult not to create retinal breaks during dissection.

(b) State of vitreous gel: In stage 5 ROP, normal vitreous architecture is totally absent and replaced by fibrosis. In stage 4 ROP however, one may see variable amount of normal looking vitreous along with fibrotic organization. A posterior vitreous detachment (PVD) is almost never present. (Had PVD occurred in the first place, TRD would not have resulted).

(c) Sub retinal blood and lipid: Bleeding into sub retinal space is not uncommon in eyes with total and subtotal retinal detachments. Frank altered blood or more commonly blood stained sub retinal fluid is seen.

(d) Fleshy Vs fibrotic disease: In some cases the exuberance of the

fibrovascular response leads to very thick and fleshy tissue that is laced with fragile frill of abnormal blood vessels. A combination of such severe proliferation with extensive retinal detachment makes it nearly impossible to dissect the tissue adequately.

(e) Secondary anterior segment changes such as - a) Progressive shallowing of anterior chamber. b) Posterior synechiae. C) Corneal opacification

Approaches to surgical management

1. Scleral buckling: The role of scleral buckling is limited. Most cases of ROP that have been lasered and yet develop TRD would have the surgical problem at or posterior to the equator and hence more amenable to vitrectomy approach rather than buckle. Few cases that have proliferation restricted to one or two quadrants but in the periphery, leading to TRD anterior to equator may benefit by scleral buckle. The aim of buckling is more to stabilize the condition rather than restoration of normal anatomy. Direct relief of such peripheral traction through vitrectomy approach will entail sacrifice of lens. Some amount of remoulding of fibrosis tends take place as long as the disease is not active and the final retinal anatomy may be surprisingly better than expected with useful visual results.

Surgical procedure: Surgery entails placement of a narrow silicone element such as #240 (MIRA implant). The band can be anchored in each quadrant either with sutures or belt loops. Since subretinal fluid cannot be drained, anterior chamber paracentesis is done to enable some degree of tightening of the band. Removal or cutting of the band is done once the condition is stable for 3-4 months in order not to impede the growth of the eyeball.

2. Lens sparing vitrectomy:⁽⁶⁾ This approach is possible for most posteriorly located TRDs. As alluded to above, this situation is more likely occur when TRD develops despite adequate laser photocoagulation. Micro incisional vitreo retinal surgical techniques are used with 23 or 25 gauge instruments and using wide-angle visualization system.

The aim of surgery is to relieve traction but not at the risk of retinal tear formation. Hence the approach is not to be too aggressive. In most cases there is no posterior vitreous detachment unless the vitreous is very degenerate and there is only fibrosis with no vitreous gel. Bimanual surgery if needed, is possible by placing a chandelier light. Simple cases with focal traction and mostly degenerate or detached vitreous are relatively easy to manage and have good results. More extensive proliferation along the

surface of retina and with no PVD can make the surgery challenging. The trade off is between leaving too much of traction unrelieved versus being aggressive and creating a retinal break- 'a most undesirable event'. However the leeway available for the surgeon is very little.

Ocriplasmin has been tried to make the dissection easier but has not shown significant advantage.⁽⁷⁾

3. Lens sacrificing vitrectomy:⁽⁸⁾ This approach is required for most stage 5 ROPs with total retinal detachment and in some cases of stage 4b as well. Closed vitrectomy and open sky vitrectomy are the approaches available to accomplish this. Most surgeons use the closed vitrectomy approach. The entry ports are usually made at limbus, although a pars placata approach is possible in a few cases. The pupil can be kept dilated with iris hooks. A few surgeons remove the superior sector of iris between the upper two entry ports to enable better access to the peripheral tissue. The lens is removed including the capsule.

Centre to periphery Vs periphery to centre approach: In general initiating the dissection near the ciliary processes is possible in open sky vitrectomy and not in closed vitrectomy. However by creating a cruciate incision in the centre and making radial extensions towards the periphery, one can get a handle for circumferential dissection across the peripheral trough. Then the tissue covering the plateau of the detached retina can be removed piecemeal. Dissecting into the funnel posteriorly can be tricky depending on how narrow the funnel is.

Additional maneuvers

The sub retinal fluid can be drained. This step may be needed in some cases after some initial dissection, to facilitate further dissection. These are eyes with relatively turgid sub retinal space that keeps pushing the retina forwards and not giving space to work. In most other cases, SRF drainage when contemplated is done after all dissection is complete. External drainage can be done using a 27-gauge needle along with injection of fluid into vitreous cavity.

Diathermy may be needed to control troublesome ooze. However ooze from surface of retina is allowed to stop by intermittently raising the intra ocular pressure rather than diathermising the same since the retinal necrosis that follows the application of diathermy can result in retinal break formation.

Complications

1. Complications due to general anesthesia: Considering the surgery on preterm babies with very often coexisting morbidity, the surgery should be performed in centres with good pediatric anaesthetic support. Very small babies may need post operative paediatric ICU care as well.

2. Inability to relieve traction adequately: While 100% relief of traction is very rarely obtained, adequate relief of traction is important to give a chance for the retina to reattach post operatively. Often post operatively, one sees the central retina becoming concave but with shallow retinal detachment persisting. Over time, posterior pole reattachment may be achieved. If no attachment has occurred by 2 months, it is unlikely that any further stretching of retina will take place to permit reattachment of at least the posterior pole. On occasions one may have opportunity to re-operate if the residual or recurrent fibrosis is considered amenable for easy dissection. These situations are unfortunately rare.

3. Retinal break: The most important complication that spells failure in most cases is occurrence of retinal break- either as dialysis or posterior retinal break. Considering the peculiarities of the ROP anatomy, these retinæ are often not amenable for fluid air exchange and reattachment of retina- especially in stage 5 ROP.

Occasional cases of stage 4a and 4b may be amenable for complete dissection of fibrotic tissue and may give opportunity to reattach the retina with fluid air exchange followed by silicone oil tamponade.

4. Bleeding: Intra operative bleeding can be a major issue if one is operating on eyes with active disease. In stage 4a and 4b, one can inject intra vitreal anti VEGF drugs 2-3 days before surgery to reduce the vascularity and risk of intra op hemorrhage. In stage 5 with retro lental fibroplasia, it would be difficult to inject intra vitreally any drug and not risk iatrogenic retinal break due to the injection.

Very often bleeding can occur at conclusion of surgery or collects post operatively. This hemorrhage may clear or may form a nidus for reproliferation. Post operative sub retinal hemorrhage has been described after lens sparing vitrectomy done for ROP in eyes of infants that are born extremely premature (around 24 weeks gestation age and around 500 gms birth weight).⁽⁹⁾

5. Reproliferation: The main reason for failure of retina to reattach is the occurrence of reproliferation.

Results

In a series of stage 5 ROP, 22.9% reattachment was obtained after lens sacrificing vitrectomy.⁽⁸⁾ In another series of stage 4 ROP, lens sparing vitrectomy resulted in anatomical success in 74% of cases.⁽⁶⁾ This clearly demonstrates the complexity of the disease and how it rapidly changes if allowed to progress to the more advanced stages

Conclusion: The unique feature of the Indian subcontinent is the diversity in the level of neonatal care one sees across the country. On one hand we see children brought with leucocoria as the presenting feature without having undergone any kind of screening- the parents notice the white reflex and/or that the child does not fix or follow light. On the other hand we see infants developing very bad retinal detachments despite having had proper screening/ lasers/ anti VEGF etc. Although retinal detachment is the basic issue in both the situations, the pathoanatomy, the complexity of surgical problem, the approach to surgical management and the outcome of treatment all differ significantly between the two.

The surgery is very demanding and frustrating both for the surgeon and the parents. However the cases with successful outcome and the joy of seeing these children later in life with mobile and functional vision is what keeps the surgeon going and attempting to continuously improve the success rate.

References

1. Harnett ME. Advances in understanding and management of retinopathy of prematurity. *Surv ophthalmol.* 2017; 62:257-276
2. Recchia FM, Capone A. Contemporary understanding and management of retinopathy of prematurity. *Retina.* 2004;24:283-292
3. Harnett ME, Mccolm JR Fibro vascular organization in the vitreous following laser for ROP- implications for prognosis.. *Retina* 2006;26:S24-31
4. Yokoi T, Katagiri, S Hiraoka M, Nakayama Y, Hosono K, Hotta Y, Nishina S, Azuma N. Atypical form of retinopathy of prematurity with severe fibro ascular pfoliferatio in the optic disc region. *Retina* 2017;0:1-8
5. Joshi MM, Ciaccia A, Trese MT, Capone A. Posterior hyaloid contracture in paediatric vitreoretinopathies. *Retina,* 2006;26:supplement 38-41
6. Bhende P, Gopal L, Sharma T, Verma A, Biswas RK. Functional and anatomical outcomes after primary lens sparing vitrectomy

for stage 4 retinopathy of prematurity. *Ind J Ophthalmol.* 2009; 57:267-71

7. Drenser K, Girach A, Capone A. A randomized, placebo controlled study of intravitreal ocriplasmin in pediatric patients scheduled for vitrectomy. *Retina* 2016;36:565–575.

8. Gopal L, Sharma T, Shanmugam M, Badrinath SS, Sharma A, Agraharam SA, Choudhary A. Surgery for stage 5 retinopathy of prematurity: the learning curve and evolving technique. *Ind J Ophthalmol.* 2000;48:101-6

9. Harnett ME, Board RJ, Houghton O. Subretinal hemorrhage after lens sparing vitrectomy in infants born at or under 24 weeks gestation. *Retina*; 2008;28:S69-74

Vitreoschisis In Diabetic PPV

Dr. Charu Gupta
Dr. Ranjan Dutta
Dr. Cyrus M Shroff

Definition

Vitreoschisis is described as splitting within the multilamellar posterior vitreous cortex during an anomalous posterior vitreous detachment (PVD). Anomalous posterior vitreous detachment leads to collapse of the liquefied vitreous body without sufficient dehiscence at the vitreoretinal surface. This leads to a split within the multilamellar posterior vitreous cortex, with the outer precortical vitreous cortex remaining attached to the retina, resulting in formation of a vitreoschisis cavity.¹ Incomplete vitreoretinal separation and vitreoschisis play a central role in the progression of common and potentially blinding diseases such as vitreomacular traction syndromes, diabetic retinopathy and proliferative vitreoretinopathy.

Vitreoschisis was first described in proliferative diabetic retinopathy (PDR) by Chu et al & Schwartz et al nearly 20 years back.^{2,3} An understanding of the process of posterior vitreous separation and vitreoschisis and identification of the appropriate surgical plane during membrane removal increases the ease and success of the dissection. With better preoperative imaging modalities and improved visual and anatomic outcomes after diabetic vitrectomies there is a renewed interest in the concept of vitreoschisis in PDR & in recognising the location & extent preoperatively.

ROLE IN PDR

Metabolic changes in diabetes mellitus lead to early liquefaction of the vitreous and cross-linking of the collagen network in a process which has been described as "diabetic vitreopathy".⁴ At the vitreoretinal interface, collagen cross-linking is partially responsible for the strong adherence between the cortical vitreous and retinal blood vessels, incomplete vitreous separation and vitreoschisis. This was first described microscopically by the

Schepens group, demonstrated ultrasonographically by Green et al, later confirmed immunohistochemically by Schwartz et al and more recently imaged in vivo by Muqit and Stanga using swept-source optical coherence tomography.⁵ This altered vitreous framework provides the scaffold for neovascularization in PDR.

In proliferative retinopathies, ischemia is the initial insult. Ischemia leads to the production of angiogenic factors like insulin-like growth factor I (IGF-I), basic fibroblast growth factor (bFGF) and vascular endothelial growth factor (VEGF). Angiogenic signal from these factors leads to the development of neovascular complexes also known as vascular epicentres. These neovascular complexes (NVC) grow into the potential space between the retina and vitreous and then invade the posterior lamellae of the cortical vitreous. With advancing disease, there is an increase in the fibrotic element. It has been documented that contraction of this fibrovascular tissue initiates vitreous contraction which leads to vitreoschisis.⁶

In normal eyes, there is a strong adhesion between the collagen fibrils of the vitreous, internal limiting membrane (ILM) of the retina and the Muller cell cytoplasm. Faulborn and Bowald showed that neovascular proliferative tissue can grow into the collagenous lamellae of the vitreous cortex in absence of posterior cortical vitreous detachment.⁷ As illustrated in Figure 1, traction on the neovascular complex ruptures the fragile new blood vessels and results in haemorrhagic dissection of the vitreous lamellae and formation of a haemorrhagic schisis cavity with the inner wall being called anterior leaf of vitreous cortex (ALVC, pseudohyaloid) and the outer wall being called the posterior leaf of vitreous cortex (PLVC, true posterior hyaloid). It has been hypothesized that this would occur only if the bond between the ILM and the posterior hyaloid was stronger than the mechanical union of the vitreous lamellae.⁹

The presence of vitreoschisis or incomplete vitreous separation causes continued traction on the vessels leading to recurrent vitreous haemorrhage and continuing fibrosis leading to tractional retinal detachment (Fig 2A). Tractional forces may also cause retinal breaks to form adjacent to vitreoretinal adhesions at the vascular epicentres, creating a combined tractional rhegmatogenous retinal detachment (Fig 2B).

Remission of PDR with regression of new vessels in cases where a complete posterior vitreous detachment is present proves the role of incomplete vitreous separation in progression of tractional retinal detachment.

Degree of Posterior Vitreous Separation

Besides vitreoschisis, the approach to diabetic vitrectomy is influenced by the degree of posterior vitreous separation and the number and type of vitreoretinal adhesions (Table 1). Abrams found that only 8% of patients with PDR have a complete vitreous separation. 22% of patients had minimal or no PVD, in 31% there was a partial vitreous separation with attachment at both the posterior pole and midperiphery. Detached vitreous at midperiphery with persistent attachment at posterior pole was the commonest presentation (39%).⁸

Types of Vitreoretinal Adhesion

Vitreoretinal adhesions may be focal (point like) or broad (epiretinal membrane surrounding the adhesion). Focal vitreoretinal adhesions are found in 86% of eyes. It may be a single adhesion or multiple focal adhesions. Focal adhesion may or may not be associated with tractional retinal detachment. Broad adhesions are further subdivided into those associated and those unassociated with folding of underlying retina. Broad vitreoretinal adhesion without folding of the retina is the least common form of attachment and probably arises from large patches of surface neovascularization. Broad vitreoretinal adhesions with folding of the underlying retina and associated detachment are formed by coalescence and contraction of the fibrotic posterior hyaloid between multiple focal vascular epicenters. The surface of the adhesion may appear smooth and thickened but the retina beneath is thrown into folds.^{6, 8} This is usually associated with tractional retinal detachment and is best approached by a bimanual technique.⁹

Other factors influencing dissection are presence, extent and chronicity of retinal detachment, presence of vitreous haemorrhage and degree of active neovascularization.^{6,8}

IMAGING

Documentation of vitreoschisis cavity is important as failure to recognise it could lead to removal of only the pseudo posterior hyaloid leaving the outer wall of the cavity and intervening vitreous cortex. This remaining layer of tissue would serve as a scaffold for continued neovascular proliferation and persistent tangential traction leading to increased incidence of postoperative haemorrhage, retinal detachment, reproliferation of membranes and anterior hyaloidal fibrovascular proliferation (AHFVP).^{1,2}

In eyes with vitreous haemorrhage, ophthalmic ultrasound is a useful imaging modality to define the morphology of the vitreous body and the vitreoretinal relations. Green et al described echographic features of vitreoschisis. The vitreoschisis cavity is characteristically filled with unclotted blood. Since the kinetic and reflectivity parameters of the anterior leaf of vitreoschisis cavity and posterior leaf of vitreoschisis cavity are similar (medium reflectivity), it is important to identify the detachment of both these layers from the retinal surface either on initial or serial examinations (Fig 3). In some eyes, the inner wall of the vitreoschisis cavity is adherent to the apex of the most highly elevated area of TRD suggesting that the inner wall of the vitreoschisis cavity may itself cause clinically significant vitreoretinal traction independent of the presence of posterior cortical vitreous separation.^{1,10}

Schwartz et al identified vitreoschisis during surgery in 81% of patients with PDR and tractional retinal detachment though ultrasonographically the incidence of vitreoschisis in the same set of patients was 17%.² They obtained tissue specimens at vitreous surgery and with immunochemical staining documented that the wall of the vitreoschisis cavity was composed of type II collagen. The reason for the discrepancy in incidence of vitreoschisis during surgery and in preoperative ultrasound is two-fold; first the severity of disease process with multiple membranes and attachments makes diagnosis difficult. Second, the thinness of the wall of the vitreoschisis cavity falls below the level of resolution of standard ultrasound.²

More recently OCT has been used to document vitreoschisis in vitreomacular traction syndromes. Muqit et al demonstrated for the first time on swept-source OCT (SS-OCT - Atlantis DRI-OCT-1, Topcon, Japan) microstructural tomographic features of and spatial vitreoretinal relationships between vitreoschisis, retinal and optic nerve head neovascularisation, detachment of the internal limiting membrane (ILM) and traction on the neuroretina in PDR. Hyper-reflective neovascularisation at the optic disc (NVD) loops and complexes, split within the posterior cortical vitreous

which is visualised as two distinct hyper-reflective bands and vitreopapillary traction were some of the findings demonstrated.¹¹ The SS-OCT characteristics of vitreoschisis and vitreoretinal traction correlate with the ultrasonography features reported by Chu and coworkers. However, its use is limited to patients with no or minimal vitreous haemorrhage.

Vitreoschisis on OCT is seen as multilayered posterior hyaloid face reflectivity (Fig 4). In a study on tomographic association of neovascularization to the posterior vitreous in PDR, Pereira et al found that in 61 of 77 eyes (79%) neovascular complexes (NVC) had grown along the outer surface of the posterior hyaloid face and vitreoschisis was seen in 37 of 77 eyes (48%). Of the 37 neovascular scans which showed vitreoschisis, 23 (62%) showed traversal of the most posterior interface (posterior hyaloid face) by the NVC, so that the complex was seen to invade the vitreoschisis cavity and, in a proportion of cases, the well-formed, intermediately reflective cortical vitreous.

SS-OCT also enables the differentiation between retinoschisis and retinal detachment, the identification of an outer vitreous layer in areas of cleavage in the posterior cortical vitreous, and the visualisation of neovascular complexes/adhesions (Figs 5, 6). These are important landmarks for avoiding iatrogenic retinal breaks, persistent vitreoretinal traction and vitreous haemorrhage following primary pars plana vitrectomy surgery in advanced cases of PDR.¹¹

SURGICAL APPROACH

Microincision vitreous surgery with 23 gauge or 25 gauge is the procedure of choice for diabetic vitreous haemorrhage with or without TRD.

A core vitrectomy is done using a noncontact wide angle system. After the vitreous haemorrhage has been cleared and the anterior vitreous removed in the line of sclerotomies, an attempt is made to identify the anterior leaf of vitreoschisis in the mid periphery. In most cases it is easier to identify this layer temporally as the separation from the retina is more marked here. After an opening is made it is extended circumferentially. After the subhyaloid space is opened it is important to clear the subhyaloid haemorrhage before enlarging the 'can opener'. In cases where there is incomplete vitreous separation it may not be possible to isolate the membrane from the periphery all around. Base excision with scleral depression is done in all cases and may be repeated in patients where separation of the hyaloid from the periphery was not obtained initially. A thorough base excision is an important step as it improves peripheral visualization, enabling easier detection of retinal breaks and more complete

laser treatment. It also decreases chance of immediate postoperative bleed and incidence of anterior hyaloidal proliferation.

Further surgical manoeuvres are usually determined by the degree of posterior vitreous separation.

Presence of complete PVD

This seems the simplest of all vitrectomies but carries a potential risk of postoperative recurrent vitreous haemorrhage. Often the PVD is not complete and a thin layer of cortical vitreous is adherent to the retinal surface. It is advisable to always check for loose edge of hyaloid after vitrectomy is done. Some surgeons advocate the use of Triamcinolone to check for residual hyaloid. In some cases of dense vitreous haemorrhage, after removal of the hemorrhage, a thin translucent layer with mild greying of the retinal surface and dull reflex of retinal vessels is seen. This is the thin residual cortical vitreous. It is best to leave this layer as removal could be more traumatic- it usually fragments and does not come off in sheets.

Partial PVD with attachment at midperiphery and posterior pole

Bimanual membrane delamination is indicated for tackling these patients with extensive membranes. With the self-retaining endoillumination in place, the membrane dissection is started from an area where the membrane has been isolated from the periphery. In most situations it is easier to start dissection superiorly and progress inferiorly. When starting dissection it is important to keep the concept of vitreoschisis in mind so as to identify the correct surgical plane at the outset, as this makes dissection quite atraumatic. Posterior leaf of vitreoschisis is usually seen as a whitish sheet or sheen over vessels. At the edge of TRD when the anterior leaf of vitreoschisis is held with a forceps, the posterior leaf, which gives a glistening reflex, gets tented and visible. This is then teased out with a scissors (Fig 7). Blunt dissection with arms of the scissors closed helps to create an edge & the correct surgical plane is created. Cutting into this tissue to get an edge invariably leads to a break. Finding the correct plane improves visualization of the vascular epicentres. Raising the membrane with forceps close to these epicentres makes dissection with the scissors precise and avoids inadvertent damage to retinal vessels. Contraction or fibrosis of these membranes by preoperative anti-VEGF also expedites dissection and reduces bleeding. Preoperative assessment by SS-OCT can help in planning surgery. It can be used to determine the safest area to start dissection. Preoperative knowledge of the vitreoretinal adhesions- number, location, extent - focal or broad and associated retinoschisis is helpful while separating the

hyaloid and later during bimanual dissection (Fig 5, 6). While dissecting vascular epicentres special care is taken along the major vessels and the optic disc. Along the major vessel if a clear separation between the membrane and retina is not visible it may be safer to isolate and coagulate the attachment. It should be ensured that it is not a broad attachment holding retina and if such is the case a careful segmentation is done.

Partial PVD with attachment at disc

Approach to these patients is similar to those who have complete PVD. Removing the disc stalk often helps in removal of cortical vitreous. Fibrovascular tissue overlying the disc is often removed with forceps. Bleeding is controlled by raising bottle height. Removing the stalk relieves peripapillary traction, removes thin cortical vitreous around the disc (Fig 8) and decreases chance of postoperative bleeding. There has been no unfavourable visual outcome despite the reported presence of axons in histopathology specimens of optic disc stalk.¹² If adhesion to disc is very firm it may be preferable to trim the proliferative tissue as removal may in extreme cases cause avulsion of the optic disc

Minimal or no PVD

This is the most difficult situation to tackle and has the worst prognosis. In some cases an opening is created in the posterior hyaloid often close to the disc. A thin layer of haem is often a good pointer to an area of minimal vitreous separation. The hyaloid is held at or close to the disc with the forceps and the small gauge cutter creates a separation between the hyaloid and retina. Rarely there is an area of separation in the periphery which can be then be extended posteriorly.

CONCLUSION

Proliferative diabetic retinopathy modifies relative interlamellar adhesion strengths at the vitreoretinal interface, giving rise to anomalous, partial posterior vitreous separation. Complete surgical delamination in diabetic eyes frequently requires careful exploration of the retinal surface to identify the correct surgical plane. This improves the ease and safety of the surgical procedure. Recognition of the concept of vitreoschisis helps in decreasing postoperative complications like recurrent vitreous haemorrhage, re proliferation of membranes, retinal detachment and anterior hyaloidal proliferation. With the advent of SSOCT, thorough preoperative recognition of OCT features may help to optimize surgical approach and outcomes.

REFERENCES

1. Sebag J, Gupta P, Rosen R et al. Macular holes and macular pucker: the role of vitreoschisis as imaged by optical coherence tomography/scanning laser ophthalmoscopy. *Trans Am Ophthalmol Soc* 2007; 105:121-131.
2. Chu TG, Lopez PF, Cano MR et al. Posterior vitreoschisis. *Ophthalmology* 1996; 103:315-22.
3. Schwartz SD, Alexander R, Hiscott P et al. Recognition of vitreoschisis in proliferative diabetic retinopathy. *Ophthalmology* 1996; 103:323-8.
4. Sebag J. Diabetic vitreopathy. *Ophthalmology* 1996; 103:205-6.
5. Pereira S, Dansingani K, Chen K et al. Tomographic relationships between retinal neovascularization and the posterior vitreous in proliferative diabetic retinopathy. *Retina* 2017; 37:1287-1296.
6. Elliott D, Lee MS, Abrams GS. Proliferative diabetic retinopathy: principles and techniques of surgical treatment. In: Ryan SJ, Hinton DR, Schachat AP, Wilkinson P, eds. *Retina*. Vol. 3. Surgical Retina. 4th ed. Philadelphia: Elsevier Mosby; 2006:2413-5.
7. Faulborn J, Bowald S. Microproliferations in proliferative diabetic retinopathy and their relation to the vitreous. *Graefes Arch Clin Exp Ophthalmol* 1985; 225:130-8.
8. Abrams GW. En bloc dissection techniques in vitrectomy for diabetic retinopathy. In: Lewis H, Ryan SJ, eds. *Medical and surgical retina: advances, controversies, and management*. St. Louis: Mosby; 1994: 304-320.
9. Shroff C, Gupta C, Shroff D. Bimanual surgery for diabetic retinopathy and vascular disorders. In: Narendran V, Kothari A, ed. *Principles and practice of Vitreoretinal surgery* 1st ed. New Delhi. Jaypee Brothers 2014; 41: 399-412.
10. Green RI, Byrne SF. Diagnostic ophthalmic ultrasound. In: Ryan SJ, ed. *Retina*, 2nd edn. St.Louis: Mosby; 1994:191-273.
11. Muqit M, Stanga P. Swept-source optical coherence tomography imaging of the cortical vitreous and the vitreoretinal interface in proliferative diabetic retinopathy: assessment of vitreoschisis, neovascularisation and the internal limiting membrane. *Br J Ophthalmol* 2014; 98: 994-997.
12. Pendergast SD, Martin DF, Proia Ad et al. Removal of optic disc stalks during diabetic vitrectomy. *Retina* 1995; 15:25-28.

Table I: Vitreous separation and vitreoretinal adhesions

Vitreous separation		
Complete PVD	Partial PVD	Minimal or no PVD
	<ul style="list-style-type: none"> • Attachment at posterior pole and mid periphery • Attachment at posterior pole 	

Vitreoretinal adhesions	
Focal	Broad
<ul style="list-style-type: none"> • Single • Multiple 	<ul style="list-style-type: none"> • Without folding of the retina • With folding of the retina

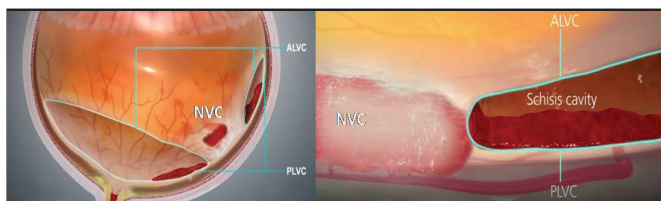
LEGENDS TO FIGURES

Figure 1; Schematic diagram showing splitting of the multilamellar vitreous cortex following bleeding from the neovascularization complex (NVC). There is formation of a vitreoschisis cavity with an anterior and posterior leaf of vitreous cortex (ALVC, PLVC).

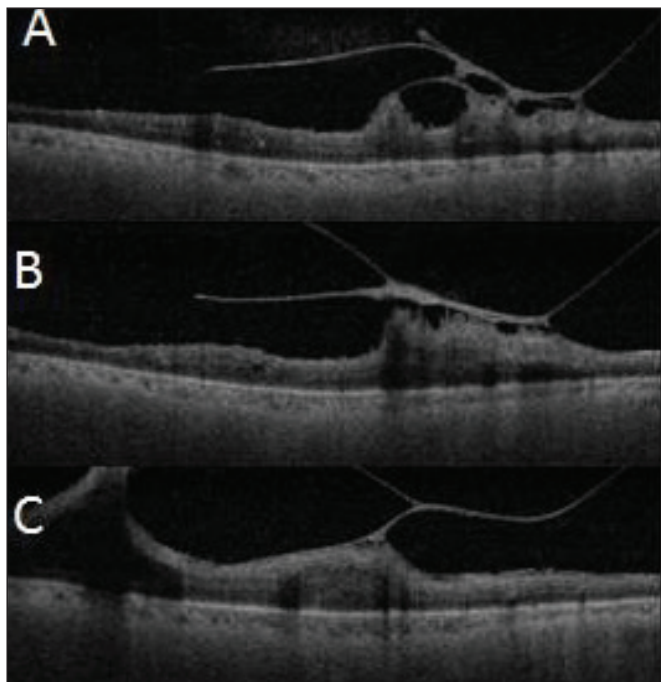


Figure 3: Preoperative SSOCT images showing varying degrees of vitreoretinal adhesions: A- focal adhesion, B- broad adhesion with fine attachments, C- totally adherent.

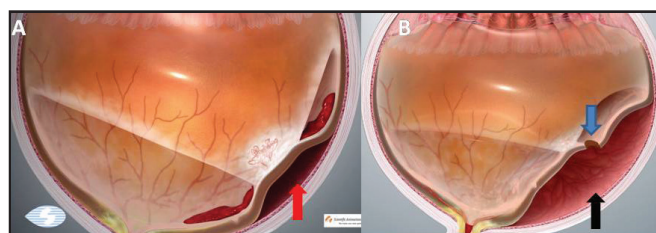


Figure 2: Schematic diagram showing traction on neovascular complex leading to formation of; A- tractional retinal detachment (red arrow); B - combined tractional rhegmatogenous retinal detachment (black arrow) with retinal break (blue arrow).

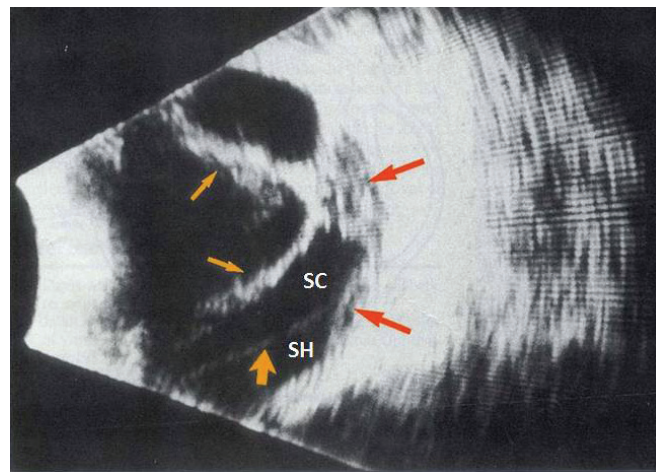


Figure 4: B scan ultrasonography picture showing vitreoschisis. SC- schisis cavity, SH- subhyaloid space, thinner yellow arrows – anterior leaf of vitreoschisis cavity (ALVC), thicker yellow arrow - posterior leaf of vitreoschisis cavity (PLVC), orange arrows – tractional retinal detachment.

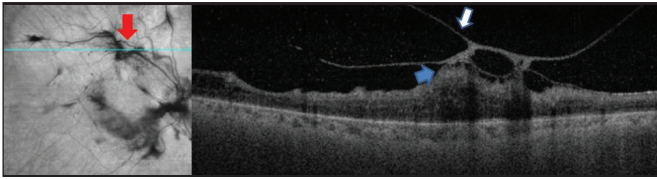


Figure 5: En face and B scan section on SSOCT showing the multilayered posterior hyaloid face with formation of vitreoschisis cavity. Red arrow depicts the neovascular complex through which the corresponding B scan is seen. White arrow depicts the pseudo plane (ALVC) through which the can opener is done. Blue arrow indicates the correct plane of dissection (PLVC).

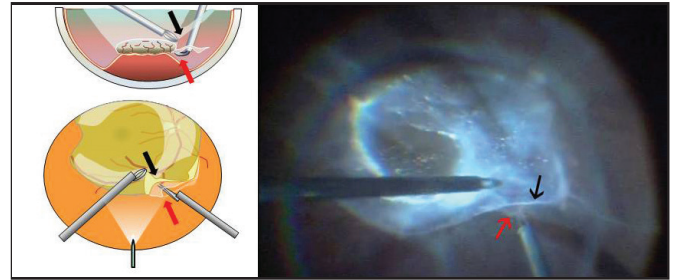


Figure 6: Schematic diagrams A, B and surgical snapshot C showing how to tease out the correct surgical plane. Black arrow shows the (ALVC) while the red arrow shows the correct plane of cleavage (PLVC).

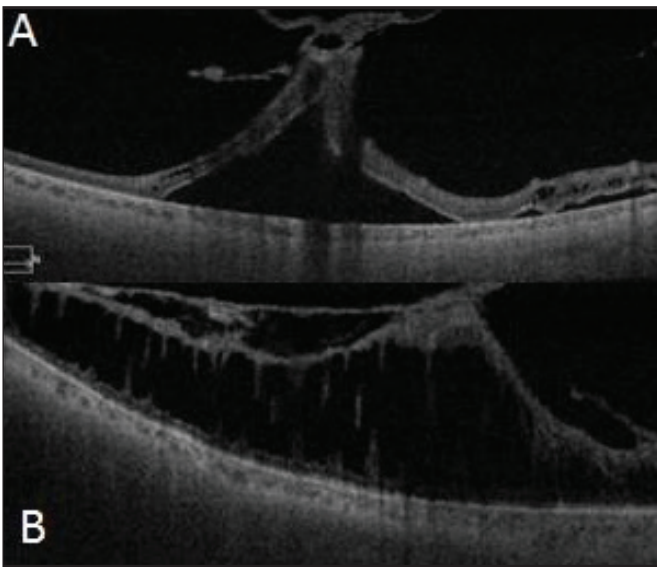


Figure 7: Preoperative SSOCT images showing vitreoschisis with: A- neurosensory detachment, B - retinoschisis. Finding the correct plane and dissection would be easier in figure A.

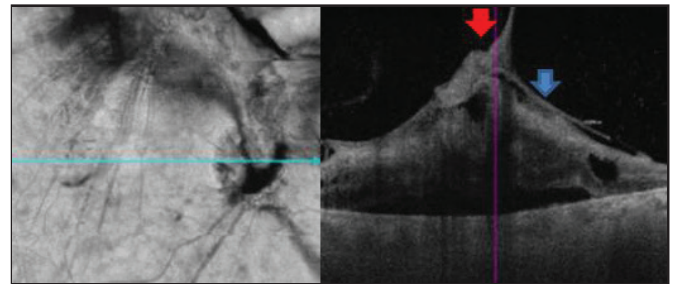


Figure 8: B scan image shows vitreopapillary traction. Fibrous stalk at disc (red arrow) is seen with thin cortical vitreous extending all around (blue arrow).

Retinectomies – All we need to know

Authors: Dr. Manish Nagpal (MS, DO, FRCS)
VR Surgeon, Retina Foundation, Ahmedabad.
Dr. Ashish Jain (DNB)

Fellow, Retina Foundation, Ahmedabad.

Running title: Retinectomies-all we need to know

Keywords: Retinectomies, PVR, RD, Retinal detachment

Abstract

Eyes with primary retinal detachment remain vulnerable to the dreaded complication of Proliferative vitreoretinopathy (PVR), which has been shown to develop in 5.1 to 11.7% of such cases. Scleral buckling and peeling of the proliferative membranes, along with the use of PFCL is often not adequate to relieve retinal traction in advanced PVR. Retinectomies are of importance to counteract tractional forces and achieve anatomic success in complicated retinal detachments.

Retinectomies – All we need to know

Eyes with primary retinal detachment remain vulnerable to the dreaded complication of PVR, which has been shown to develop in 5.1 to 11.7% of such cases. [1] A scleral buckle will sometimes adequately relieve traction to avoid cutting the retina. Scleral buckle will change the vector force of contraction of proliferative membranes so the force is no longer applied to pull the retina away from the pigment epithelium. Traction that can be easily and efficiently relieved with a scleral buckle (traction usually anterior in location and focal in extent) should be managed in such a manner; however, with extensive traction and fixed folds, a buckle is often not adequate. Also peeling of the proliferative membranes, along with the use of PFCL is often not adequate to relieve retinal traction in advanced PVR. [2, 3] In addition, the extensive dissection and time required to revise a scleral buckle may sometimes be more harmful to the eye than internally relieving traction with a retinectomy. Relaxing retinectomies, first described by Machemer [4] in 1981, are now considered as valuable tools in management of such challenging circumstances.

Retinectomy is indicated when there are extensive epiretinal membrane formations, particularly strong membrane adhesions to retina or residual retinal traction/contraction/fibrosis following membrane dissection. (Table 1)

Table 1: Indications for Relaxing Retinotomies and Retinectomies

- **Retinal incarceration in traumatic or surgical wound**
- **Proliferative vitreoretinopathy**
 - **Focal contraction (star fold)**
 - **Diffuse contraction**
 - **Circumferential contraction**
 - **Intrinsic retinal contraction**
 - **Anterior retinal displacement**
 - **Extensive fibrous periretinal proliferation**
 - **Contraction and fibrosis of flap of giant retinal tear**
- **Proliferative vascular retinopathy**
- **Inner wall of congenital retinoschisis**

Preoperative Assessment:

Detailed preoperative assessment, including previous surgeries, use of buckle, tamponade used and the grade of PVR should be noted.

Location:

Retinal pathology dictates where to position the retinectomy. It is critically important that all traction has been relieved posterior to the retinectomy site. Most commonly, retinectomies are made circumferentially at the posterior edge of a previously placed scleral buckle.

After completing thorough dissection, reassess for residual traction and intrinsic foreshortening of the retina that would prevent retinal flattening or could contribute to postoperative re-detachment. If a retinectomy is deemed necessary to achieve the surgical goals, try to identify the most anterior path because contracture inevitably results in less remaining retina than was anticipated. In cases of retinal incarceration or in some cases of localized intractable traction, a circular retinectomy is used, excising the entire area of pathology.

Doing a Retinectomy: (Figure 1)

The retinectomy should only be performed after complete membrane removal. If the retina is cut or excised before complete membrane removal, further membrane removal will be more difficult and may result in unnecessarily large retinal defects or residual membranes that may lead to re-detachment of the retina.

It is useful to be able to see the full extent of the retina to be cut or excised during creation of a retinectomy. With full visualization, it is easier to assess the best location and the necessary extent of the retinectomy. A wide-angle viewing system is ideal for visualization of the retina during this maneuver. Either a contact or non-contact system can be used. Use of a wide-angle system may reduce the time necessary to do the procedure, improve the ability to apply laser photocoagulation, and reduce the need for scleral depression. [5] Before a relaxing retinectomy is created, diathermy should be applied to the entire area to be cut. (Figure 1b) Blood vessels in the area should be occluded. Intraocular diathermy must be used at the proposed site of retinectomy to all the visible vessels to prevent bleeding. The contiguous retinal whitening that is created by the diathermy marks becomes a stencil that can be followed with the vitrector. Retinectomy is nowadays performed with vitreous cutter as anteriorly as possible in the area of retinal stiffening and extended circumferentially as far as necessary to relieve all retinal contraction and one clock hour on either side involving normal retina. (Figure 1c) It is important to plan to relieve a clock hour additionally so as to have adequate and complete relaxation of the stiff retina. Moreover before the actual

retinectomy is carried out, inspite of doing adequate diathermy, a hemorrhage may occur from the cut ends of the retina or by an inadvertent touch to the underlying choroid, in either situation the infusion pressure should be immediately raised to limit the bleeding. Further diathermy should be done to the bleeders to make sure the bleeding stops before one proceeds otherwise at times the whole surgical field and view would get fuzzy and may lead to more intraoperative complications. Residual blood can contribute to future proliferation and contracture and cauterized retina is easy to follow and remove with the vitrector. [6]

Care should also be taken to remove as much as possible of the peripheral nonfunctioning anterior retinal flap to minimize chances of ischemia, neovascularization and re proliferation. [6]

Hemostasis:

Hemostasis is achieved with raised intraocular pressure and endodiathermy, whenever needed. PFCL injection to ensure total flattening of retina beyond the cut edges of the retinectomy. Three to four rows of laser barrage must be carried out along the posterior edge of retinectomy.

Extent:

Although it is important to leave behind as much viable retina as possible, removing all areas of potentially contracted retina is equally crucial. Leaving behind significant preretinal membranes that cannot be peeled is often a mistake. If they do not involve the macula, they can be removed by including them in the retinectomized area. It is always best that the planned edge of the retinectomy be “fresh”—that is, free of any membranes, traction, or “rolling.”

The biggest mistake surgeons make when performing a relaxing retinectomy is making it too small. A 60° or less relaxing retinectomy is usually problematic, as it does not allow the retina to relax enough to deal with the traction, and the edges subsequently lift with retinal re-detachment. As most cases are inferior, bring the superior edge of the retinectomy site to at least the horizontal meridian, which helps achieve a better tamponade of the retinectomy edge with either gas or oil. Often, a 180° inferior retinectomy is necessary.

Although classically a circumferential retinectomy is done, at time radial relaxing retinectomies are also needed to relax the stiffness further if required.

Endolaser:

Common origins of re-detachment are the lateral edges of a retinectomy. This may occur due to residual or recurrent traction, insufficient size of retinectomy, insufficient tamponade, or inadequate laser retinopexy. The latter has an easy fix. Typically, two rows of laser barricade should be placed along the posterior edge, carried all the way to the ora serrata. (Figure 1d) Avoid applying excessive laser posteriorly, as hyperintense laser will increase inflammation without necessarily increasing the probability of success.

Use of PFCL:

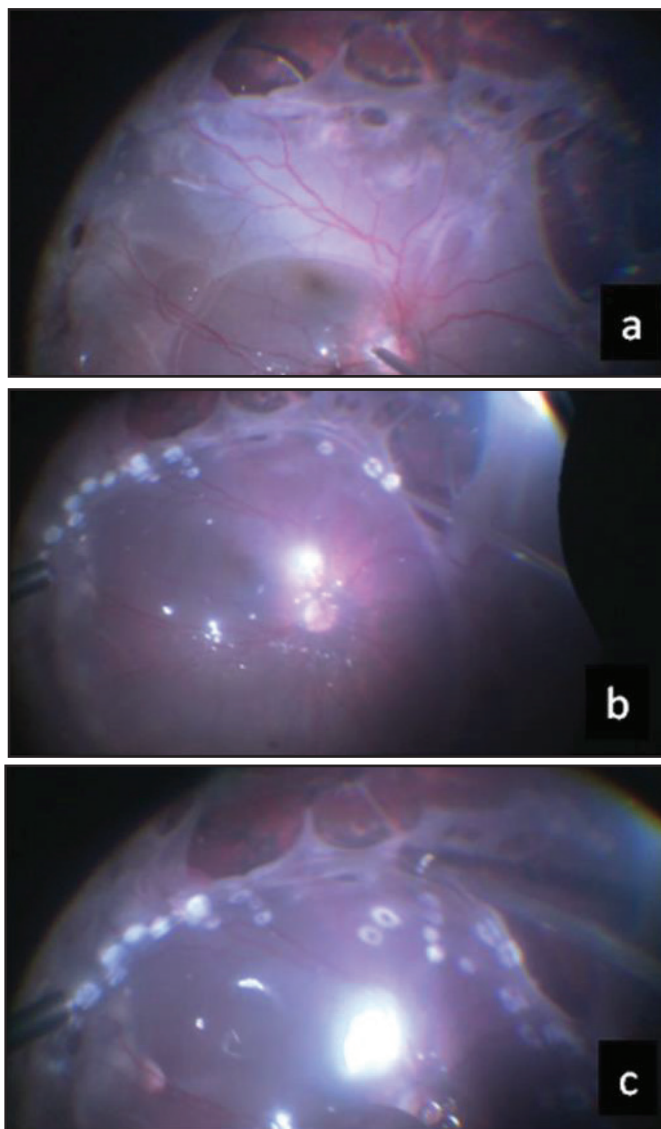
Most circumferential retinectomies benefit from the use of heavy liquid (perfluorocarbon liquid-PFCL) as an adjuvant to flatten the retina. Attempting to perform air-fluid exchange without heavy liquid often results in postoperative retinal folds due to persistent subretinal fluid. Consider placing a bubble posteriorly before making the retinectomy to determine the dynamics and “tautness” of the retina.

Tilting the eye away from the retinectomy while infusing PFCL helps to ensure that all subretinal fluid is squeezed out. Making sure that anterior-posterior traction and tangential traction are removed prior to injecting PFCL will minimize the risk of subretinal migration of the heavy liquid. Inject Perfluorocarbon heavy liquid on the posterior pole which helps to stabilize the macula and also in case of a bleed, would prevent the blood from trickling over or under the retina instantly.

Air/PFCL or PFCL/Silicon Oil Exchange:

As in a giant retinal tear case, the air-PFCL exchange is one of the most critical and underrated steps of retinectomy. As air is infused from above, aspiration should start at the top of the fluid phase. (Figure 1e) The aqueous on top of the PFCL meniscus is removed first, starting at the most anterior portion of the retinectomy. As the exchange continues, deliberately move your extrusion cannula more posteriorly, making sure that you maximize removal of subretinal fluid at each position. You will have the least residual fluid if you rotate the eye in the direction of the retinectomy, similar to what you might do with a drainage retinotomy during a more routine rhegmatogenous retinal detachment repair. It is also beneficial to drain both edges of the retinectomy. For example, if an inferior 180° retinectomy is performed, make sure to extrude using the technique described above at both the 3- and 9-o'clock locations. Once the edges are dry then

further aspirate the residual PFCL till the disc. Once the chamber is totally air filled, then silicon oil can be injected. Other option is to do direct PFCL/Silicon oil exchange. In this the silicon oil is pushed through infusion and the PFCL is gently aspirated. This technique reduces the chances of slippage of the retina at the edges of the retinectomy.



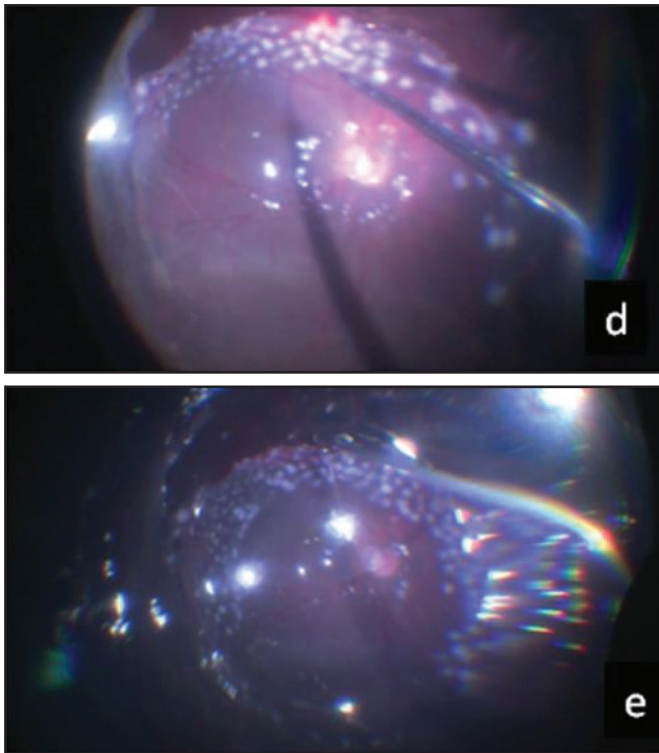


Figure 1: (a) Intraoperative photo of inferior contraction with multiple breaks. (b) Diathermy being applied prior to retinectomy. (c) Cutter being used to make a retinectomy. (d) Laser marks to the edges of retinectomy. (e) Air PFCL exchange being done.

At a Glance

- If a retinectomy is deemed necessary, try to identify the most anterior path because contracture inevitably results in less remaining retina than was anticipated.
- Always plan a wider retinectomy than what may be the obvious area of contraction
- Most circumferential retinectomies benefit from the use of heavy liquid (PFCL) as an adjuvant to flatten the retina.
- Endo diathermy is a useful tool to reduce the chances of bleeding and also to eventually stop any bleeders.
- Silicone oil is an important adjunct with these surgeries.
- Retinectomies are of equal importance to counteract tractional forces and achieve anatomic success in complicated retinal detachments. (Figure 2)

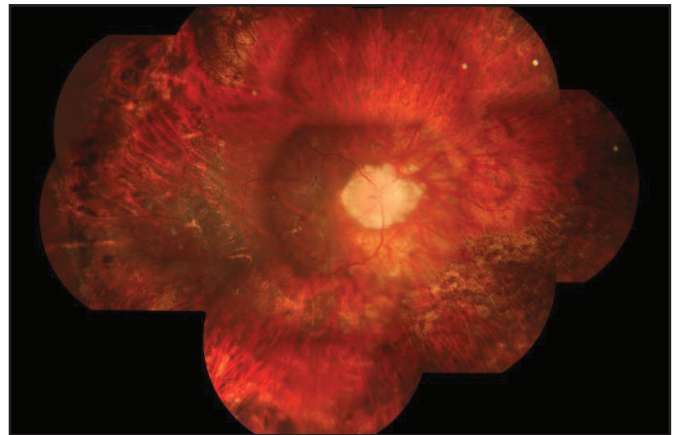


Figure 2: Post operative fundus picture after inferior retinectomy from 6-10 o'clock.

References:

1. Girard P, Mimoun G, Karpouzas I, Montefiore G. Clinical risk factors for proliferative vitreoretinopathy after retinal detachment surgery. *Retina* 1994;14:417-24.
2. Morse LS, McCuen BW 2nd, Machemer R. Relaxing retinotomies. Analysis of anatomic and visual results. *Ophthalmology* 1990;97:642-47.
3. Han DP, Lewis MT, Kuhn EM, Abrams GW, Mieler WF, Williams GA, et al. Relaxing retinotomies and retinectomies. Surgical results and predictors of visual outcome. *Arch Ophthalmol* 1990;108:694-97
4. Machemer R. Retinotomy. *Am J Ophthalmol* 1981;92(6):768-74.
5. Lesnoni G, Billi B, Rossi T, et al. The use of panoramic viewing system in relaxing retinotomy and retinectomy. *Retina* 1997;17:186-90.
6. Bourke RD, Cooling RJ. Vascular consequences of retinectomy. *Arch Ophthalmol* 1996;114:155-60.

Mellow the eyes with
the freshness of Aqua



Aquarray[®] Plus

Carboxymethyl cellulose sodium 0.5 % & Glycerin

Lubricant Eye Drop

Dry Eye Syndrome

Aquarray[®]
Lubricant Eye Drop
Carboxymethylcellulose Sodium 0.5%
with Stabilized Oxychloro Complex

Aquarray[®] gel
Eye Drop
Carboxymethylcellulose Sodium 1%
with Stabilized Oxychloro Complex

Aqua
for eyes

Raymed

Raymed Pharmaceuticals Limited

Corporate Office: SCO-859, Manimajra, Chandigarh
E-mail: info@raymedindia.com, Website: www.raymedindia.com