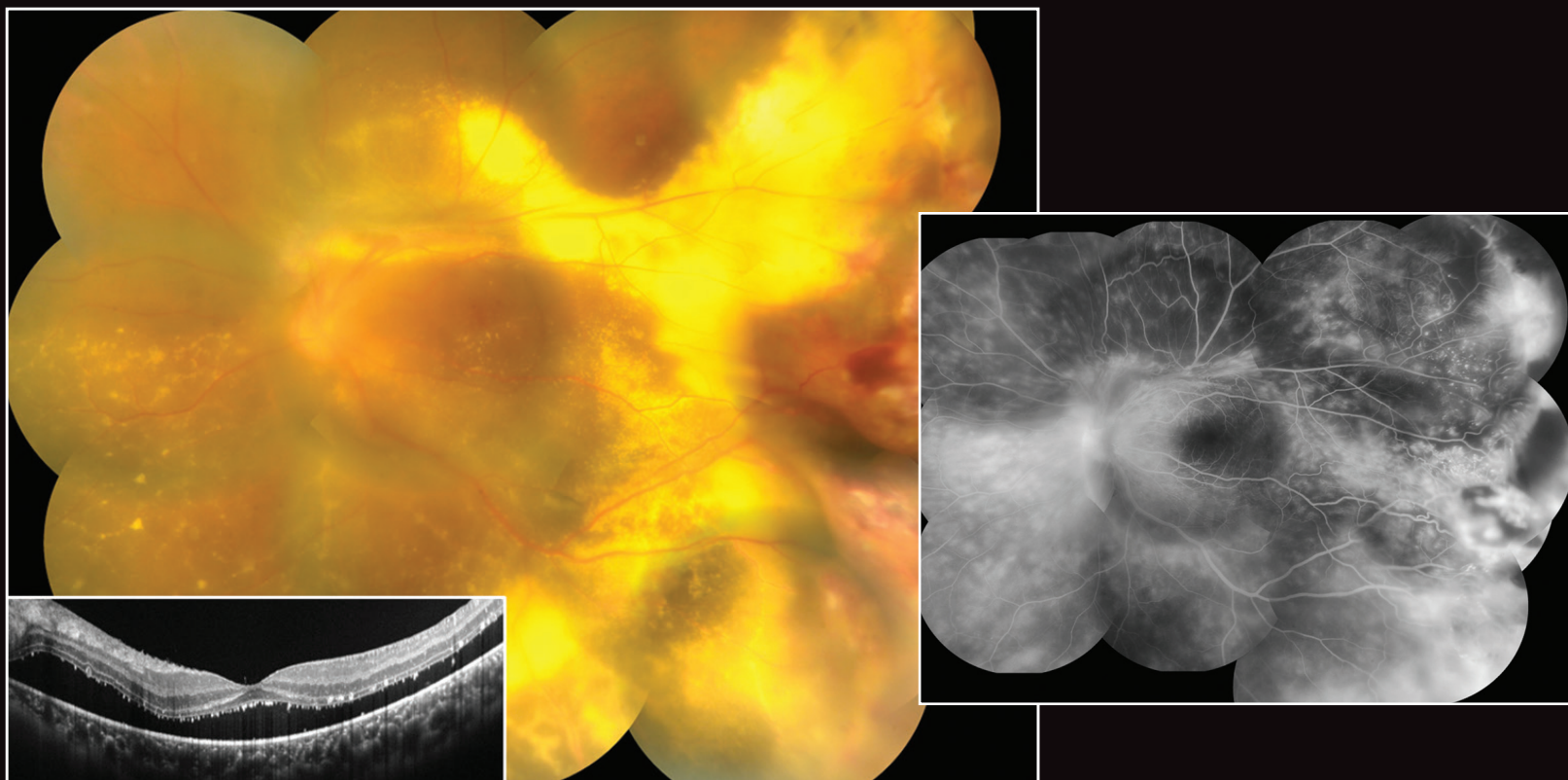


TACKLING COATS DISEASE WITH PPV



Early surgical management can be an effective option to prevent progression.

BY SHIN MIZOGUCHI, MD, PHD, AND YUSUKE OSHIMA, MD, PHD

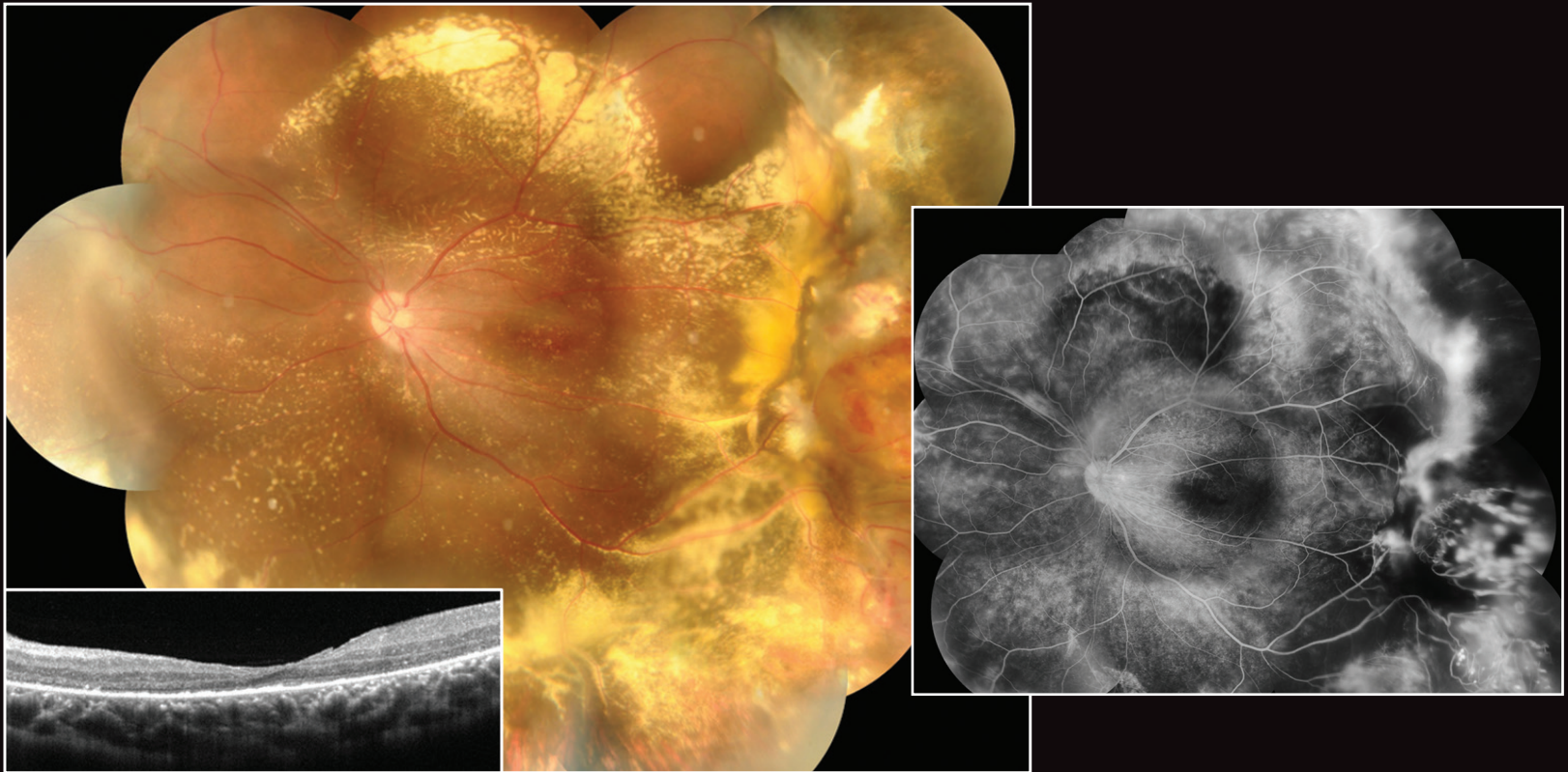
A 16-year-old male presented with a complaint of gradual vision loss in his left eye for the past 6 months. The patient's BCVA was 20/20 OD and 20/400 OS. His ocular history included a diagnosis of Coats disease in the left eye and several sessions of laser photocoagulation at other centers over the past several years.

At the initial visit to our practice, slit-lamp examination showed a normal anterior segment in each eye. Fundus examination revealed a macula-involving severe exudative retinal detachment with accumulation of prominent hard exudates and retinal hemorrhages in the left eye. Retinal folds induced by epiretinal membrane were observed around the upper vascular arcade. Retinal vascular tortuosity and telangiectasia were detected at the temporal periphery with multiple aneurysms, including a large one similar to a retinal hemangioma (Main

Figure, Above). Fluorescein angiography (FA) showed prominent diffuse vascular leakage from the telangiectasia and aneurysm (Inset, Above).

We confirmed the earlier diagnosis of Coats disease, now at stage 3A. The patient immediately underwent 25-gauge three-port lens-sparing vitrectomy under general anesthesia. Core vitrectomy with thorough vitreous shaving, brilliant blue G staining–assisted epiretinal and internal limiting membrane peeling, and segmentation and delamination of the peripheral fibrovascular membrane were conducted with a bimanual technique. This procedure was followed by endolaser photocoagulation to the aneurysm and cryoretinopexy to the giant peripheral hemangioma-like aneurysm after fluid-air exchange.

Postoperatively, the patient was instructed to remain in a prone position for 2 days. Two months after surgery, the



retina was completely attached with gradual absorption of the hard exudation (Figure, Above). The peripheral aneurysms had regressed significantly, and minimal leakage was seen on postoperative FA (Inset, Above). The patient's VA recovered to 20/40 OS without any re proliferation.

DISCUSSION

Coats disease is a unilateral retinal vascular disease characterized by retinal vascular telangiectasia and microvascular aneurysmal changes that can cause exudative and tractional retinal detachment.¹ The main treatment option for early-stage Coats disease is laser photocoagulation to the non-perfused retina to stabilize the aneurysms and decrease the permeability of the abnormal vessels.^{1,2} Intravitreal injections of anti-VEGF drugs and/or steroids can be used as adjunctive treatments for advanced cases.^{3,4}

However, progression cannot always be prevented with medical treatment. Vitreoretinal surgery can more effectively restore visual acuity in eyes with total retinal detachment (stage 3B) or more advanced stages, and these eyes should be treated at the earliest stage possible.^{1,5}

In the case presented here, we recommended vitrectomy to induce posterior hyaloid detachment and eliminate the scaffold for vitreoretinal interface proliferation. Extensive endolaser photocoagulation and cryoretinopexy without internal or external drainage may be another effective treatment option for early-stage cases that do not respond to conventional medical approaches. ■

1. Shields JA, Shields CL, Honavar SG, et al. Classification and management of Coats disease: the 2000 Proctor Lecture. *Am J Ophthalmol*. 2001;131:572-583.
2. Tipsuriyaporn B, Yonekawa Y. Widefield fluorescein angiography in Coats disease. *Retina Today*. 2020;15(1):10-11.
3. Lin CJ, Hwang JF, Chen YT, et al. The effect of intravitreal bevacizumab in the treatment of Coats disease in children. *Retina*. 2010;30(4):617-622.
4. Sein J, Tzu JH, Murray TG, Berrocal AM. Treatment of Coats' disease with combination therapy of intravitreal bevacizumab, laser photocoagulation, and sub-Tenon corticosteroids. *Ophthalmic Surg Lasers Imaging Retina*. 2016;47(5):443-439.
5. Li AS, Capone A Jr, Trese MT, et al. Long-term outcomes of total exudative retinal detachments in stage 3B Coats disease. *Ophthalmology*. 2018;125(6):887-893.

SHIN MIZOGUCHI, MD, PHD

- Vice Director, Vitreoretinal & Cataract Surgery Center, Oshima Eye Clinic Group, Takatsuki-city, Osaka, Japan
- shinmizoguchi0216@gmail.com
- Financial disclosure: None

MANISH NAGPAL, MBBS, MS, FRCS, SECTION EDITOR

- Senior Consultant, Retina and Vitreous Services, The Retina Foundation, Ahmedabad, India
- drmanishnagpal@yahoo.com
- Financial disclosure: Consultant (Nidek)

YUSUKE OSHIMA, MD, PHD

- Founder and Director, Vitreoretinal & Cataract Surgery Center, Oshima Eye Clinic Group, Takatsuki-city, Osaka, Japan
- yusukeoshima@gmail.com
- Financial disclosure: Consultant (Katalyst Surgical, Nidek, Alcon Japan)

If you have an image or images you would like to share, email Dr. Nagpal.

Note: Photos should be 400 dpi or higher and at least 10 inches wide.